



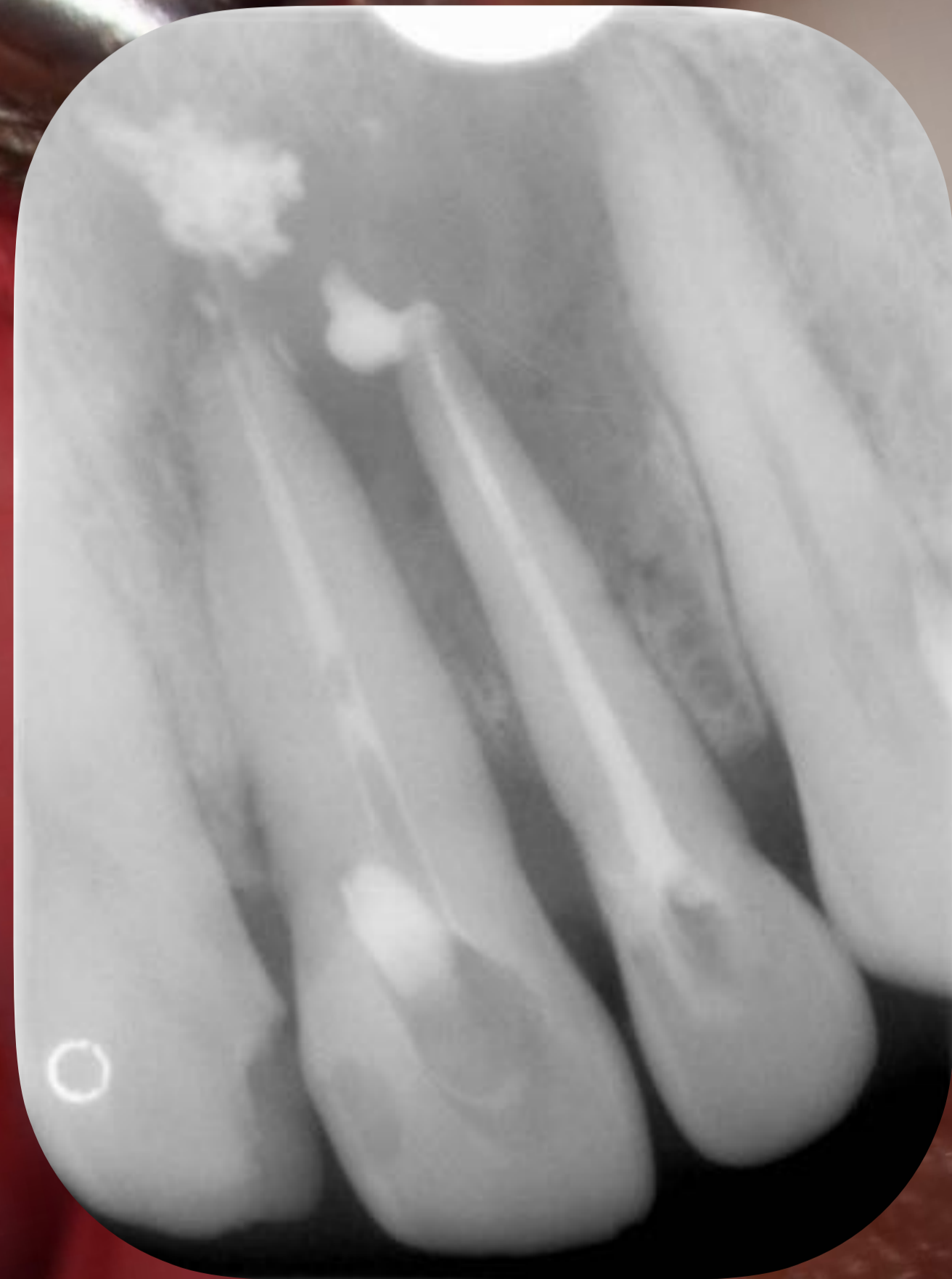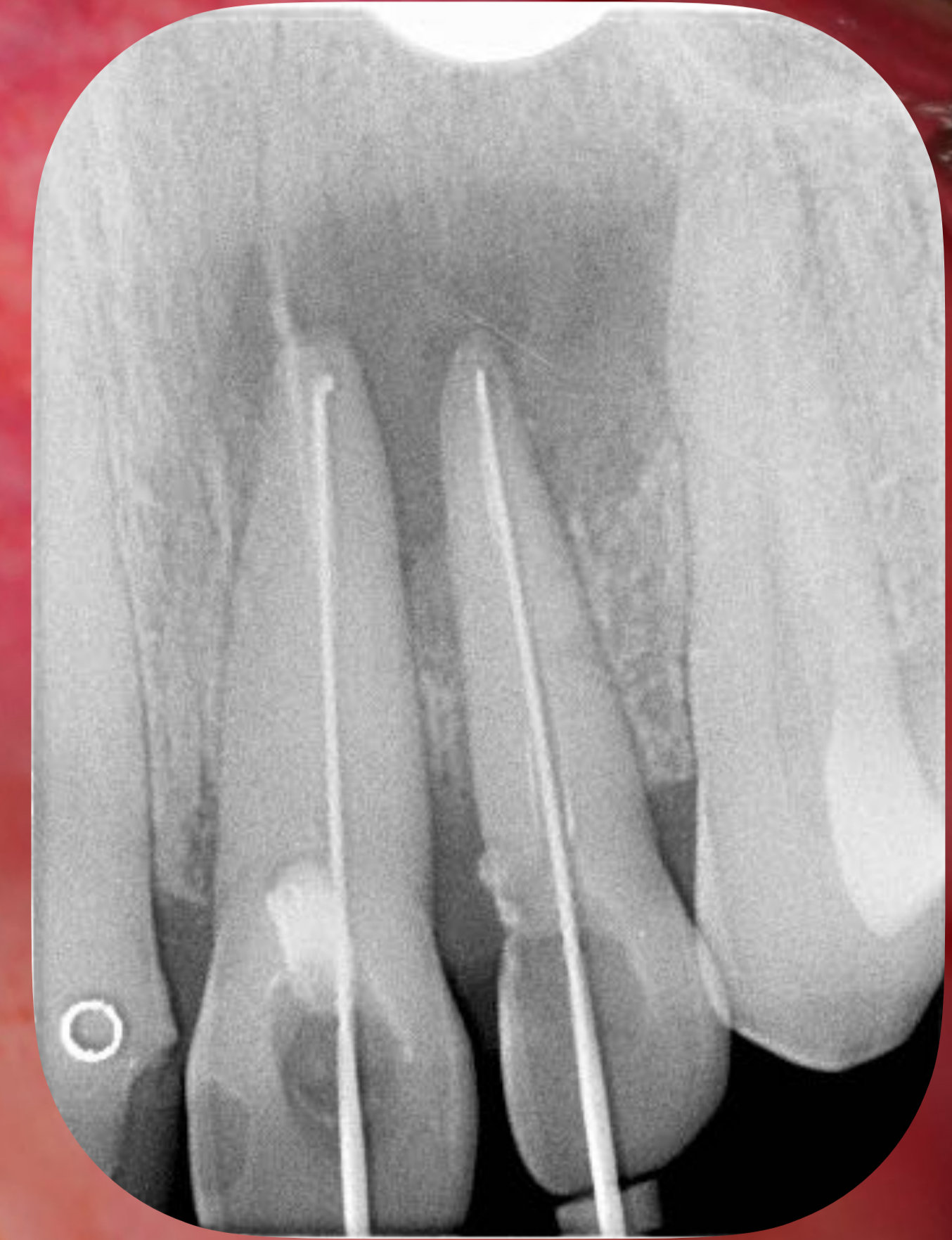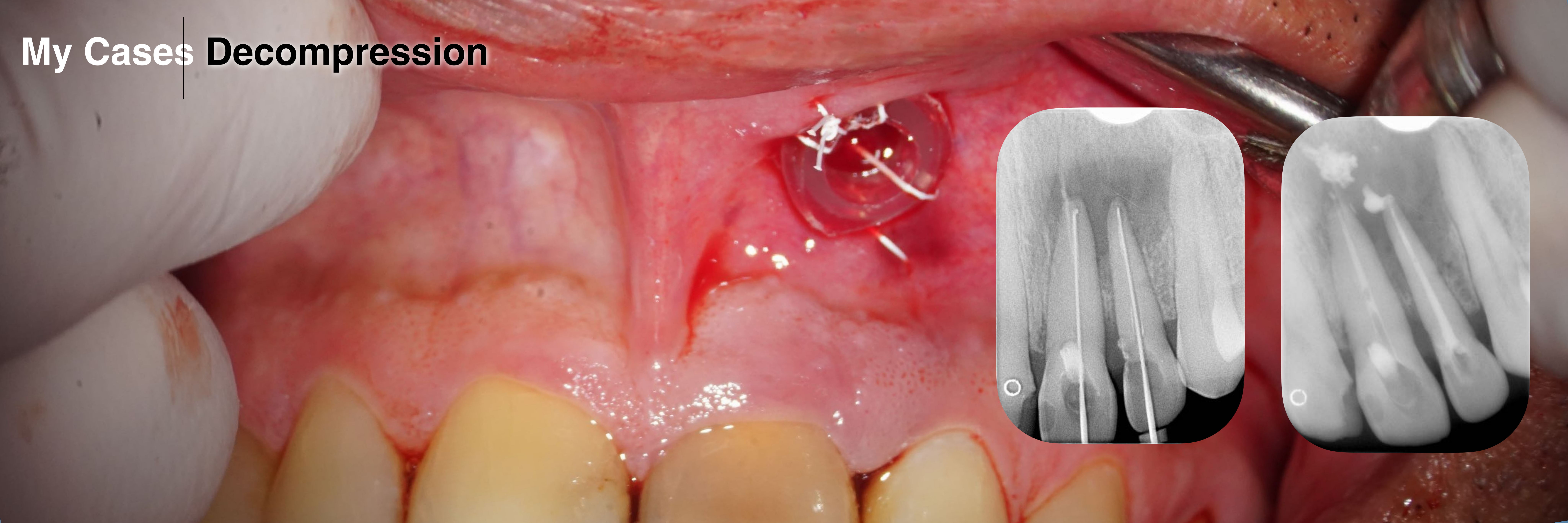
# Scope of work

Carlos Vidal Tudela

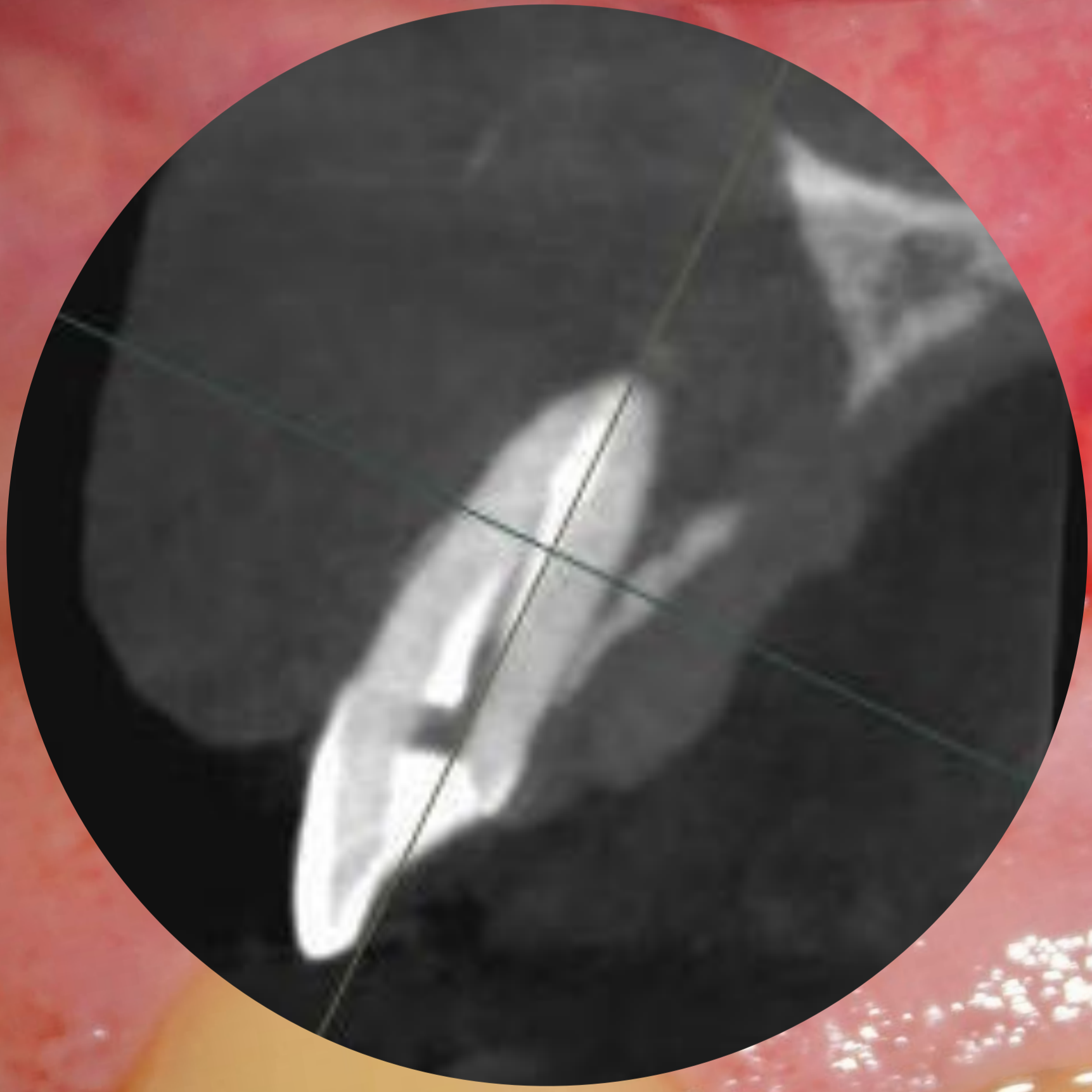


# Surgical Decompression

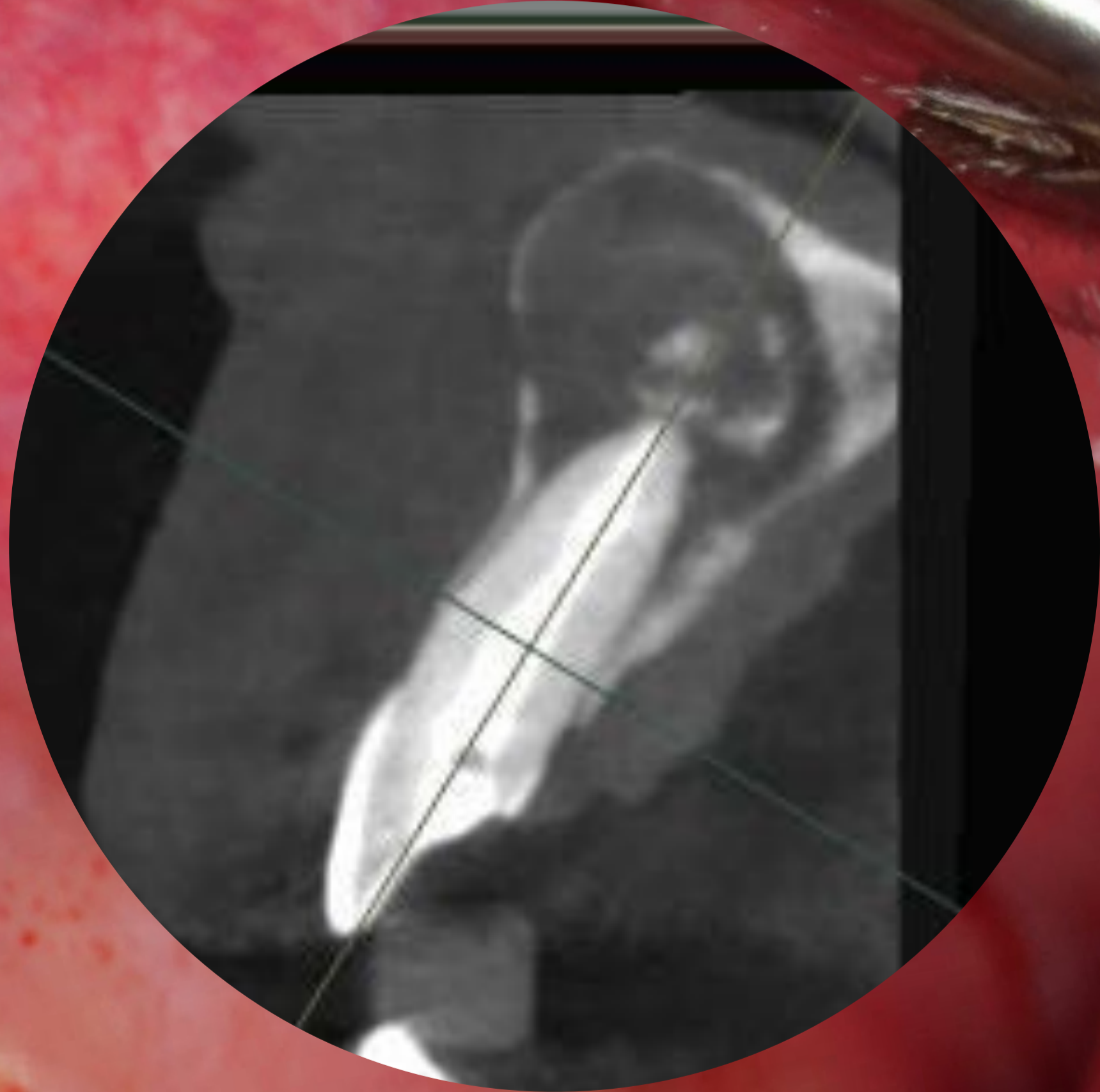
# My Cases Decompression



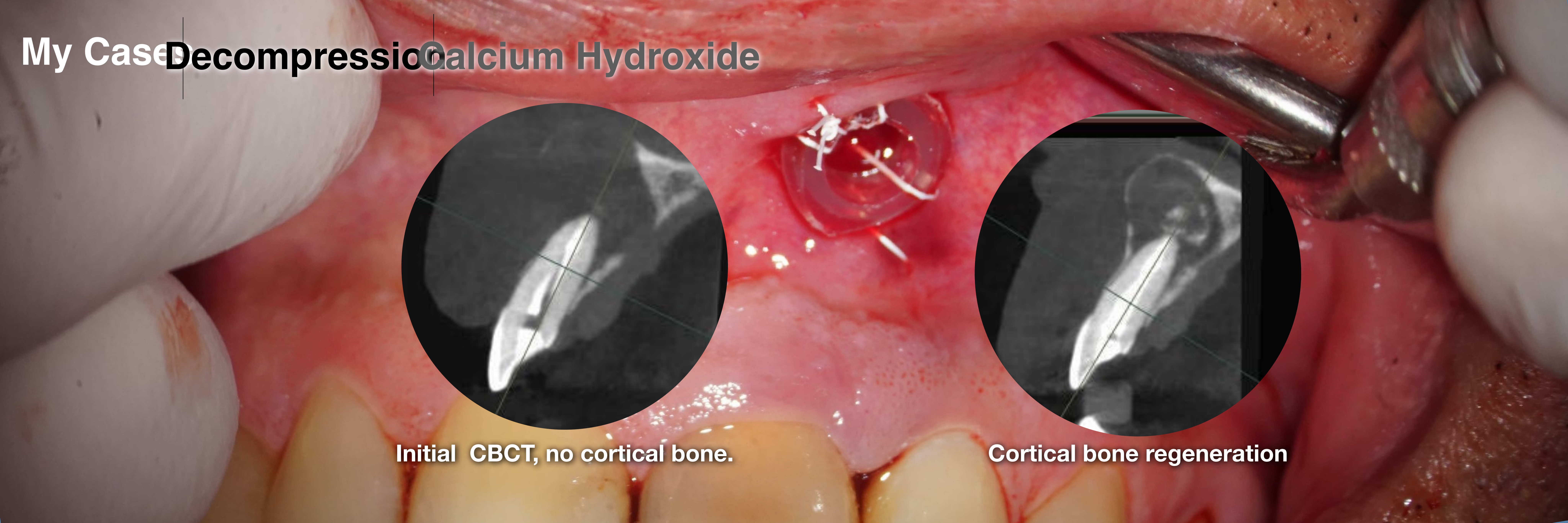
# My Case Decompression Calcium Hydroxide



Initial CBCT, no cortical bone.



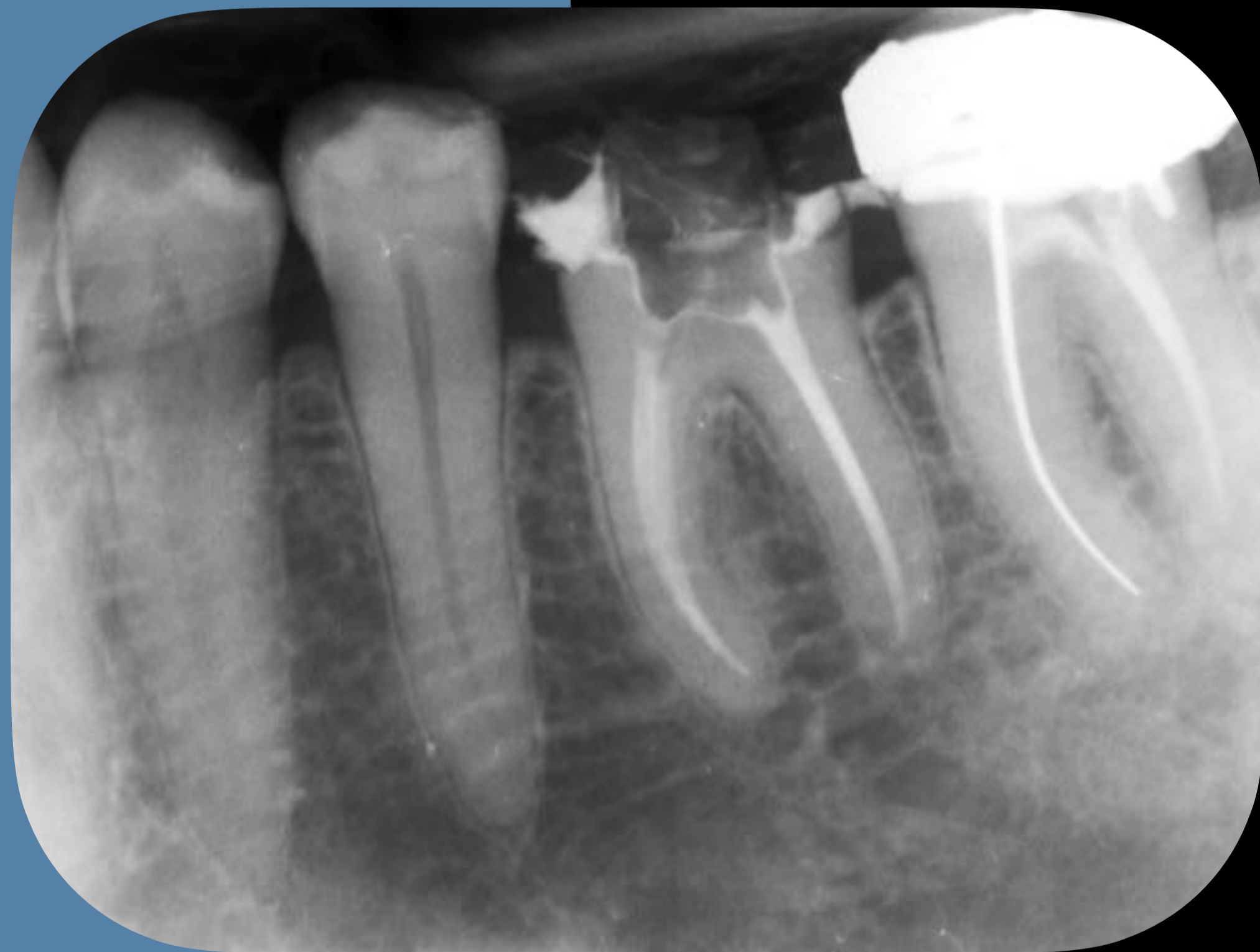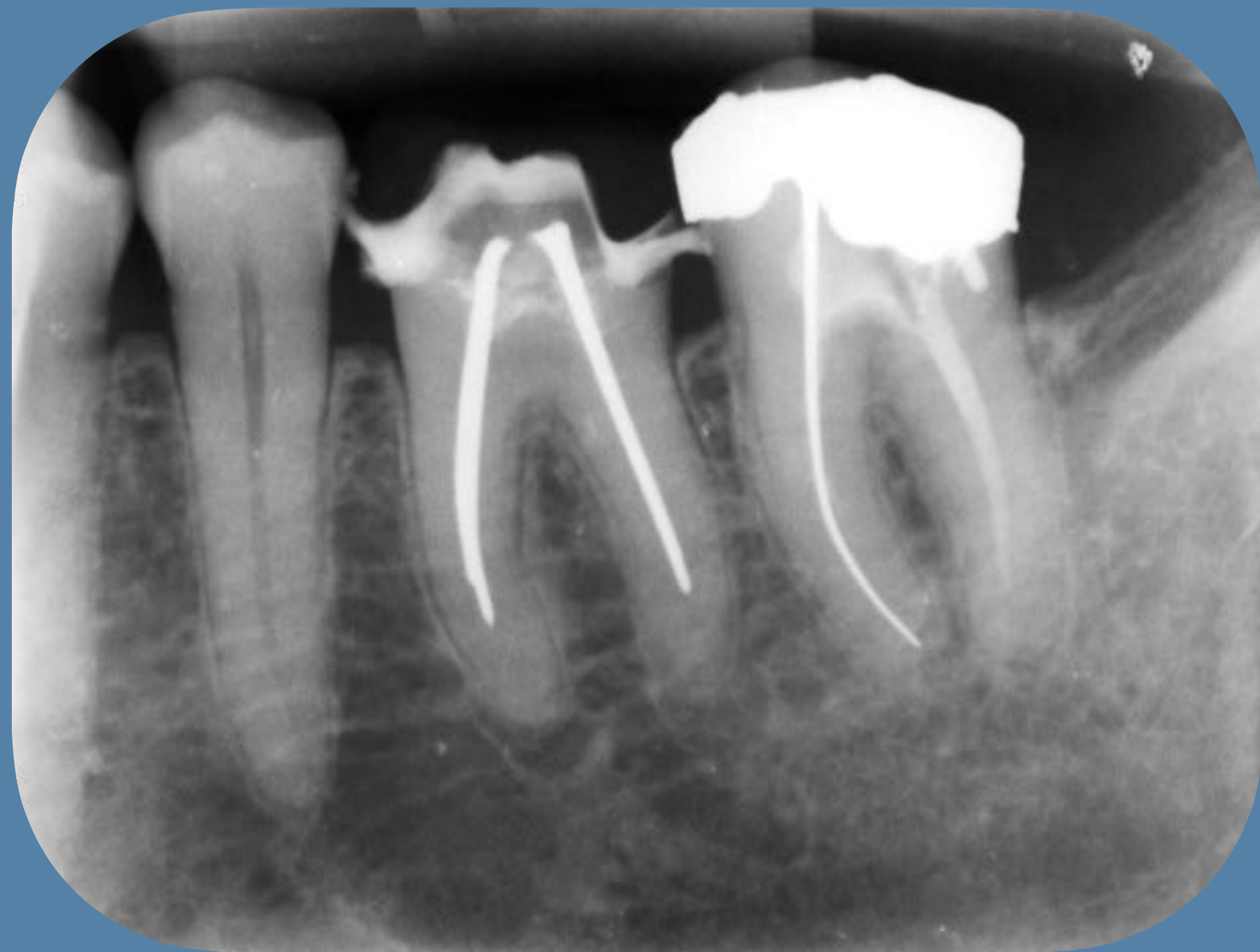
Cortical bone regeneration



2

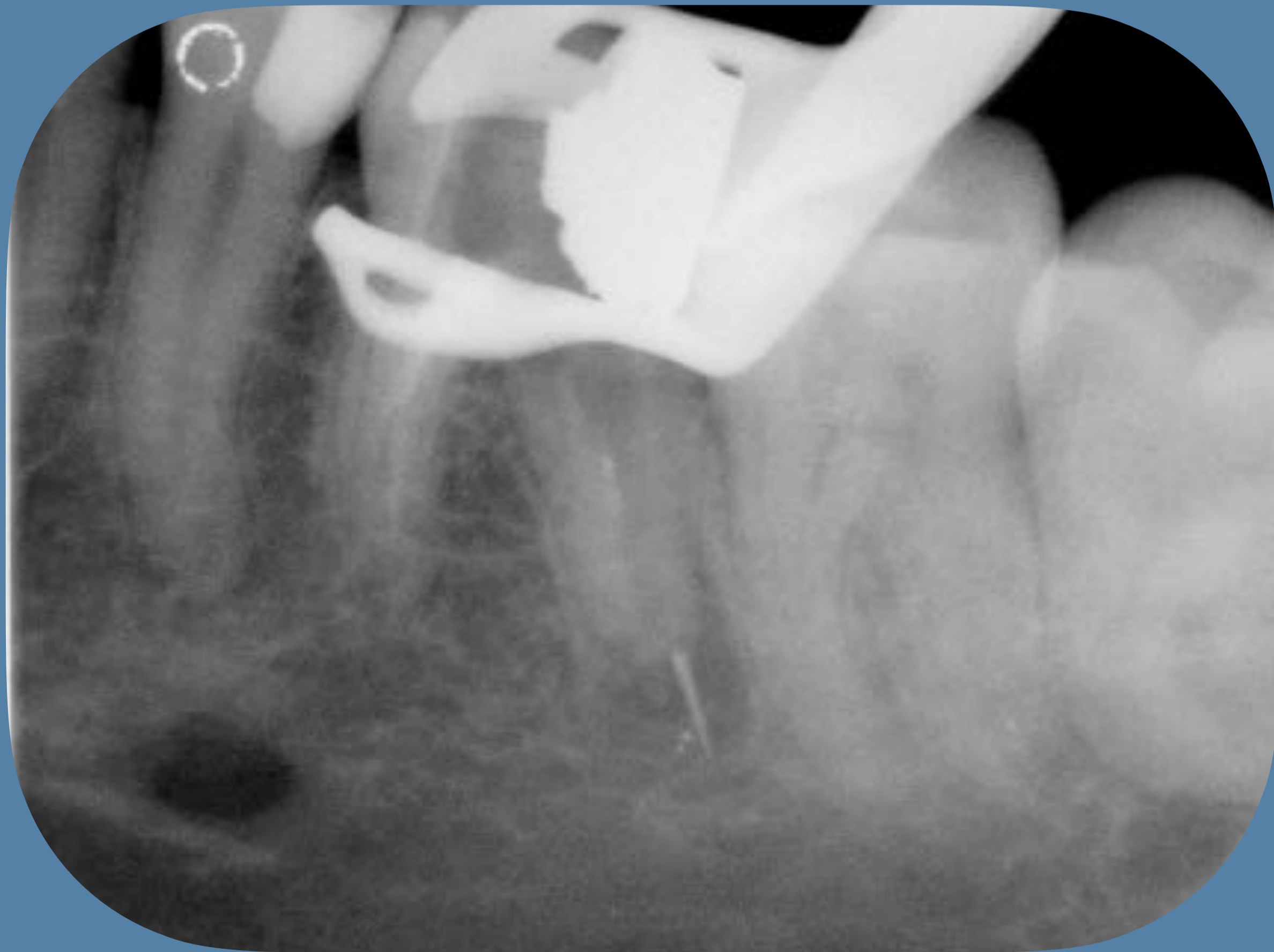
# Silver Point Retrieval

# My Case Silver Point Retrieval

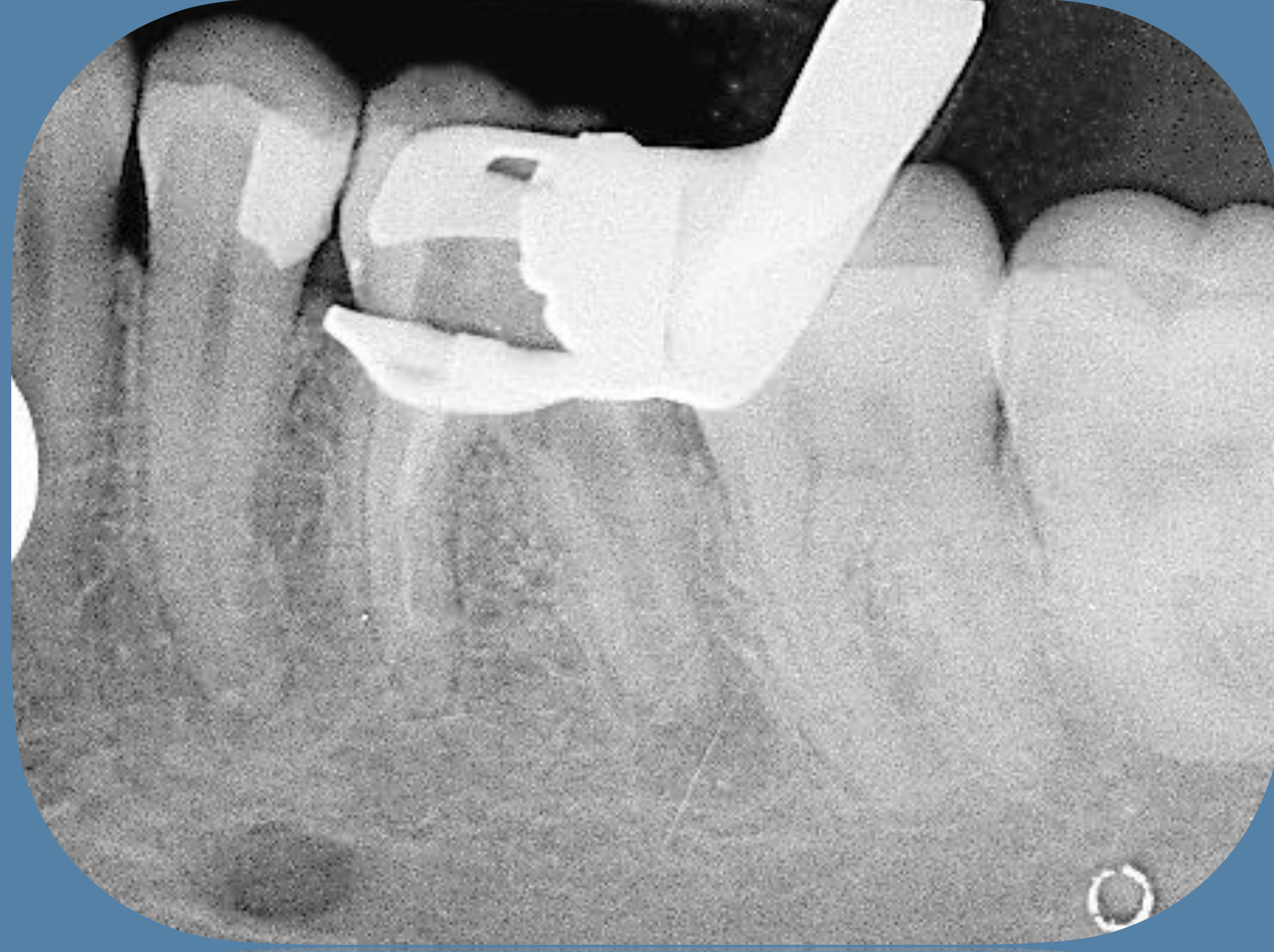

3

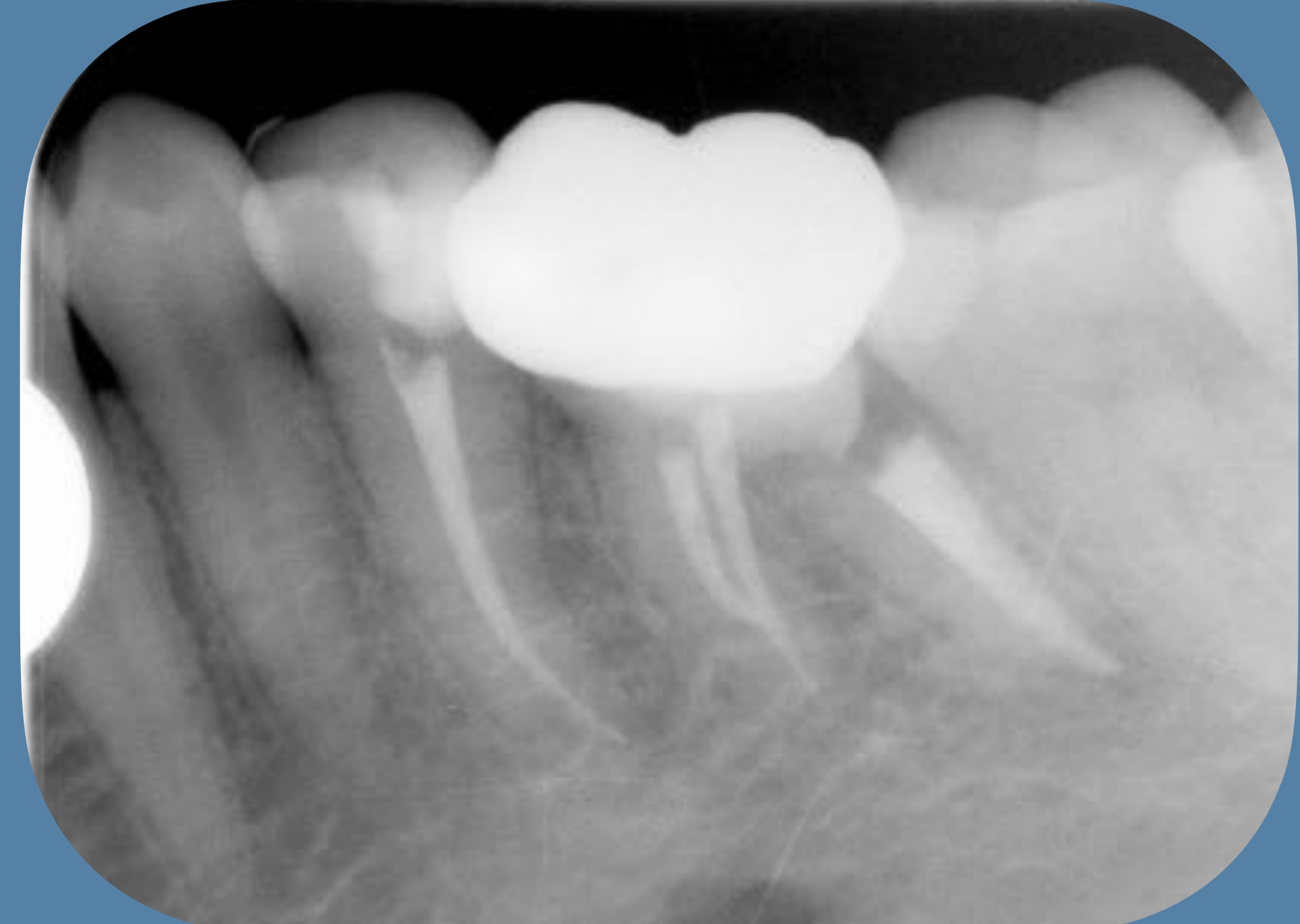
**File Retrieval**



**Initial**



**File Retrieved**

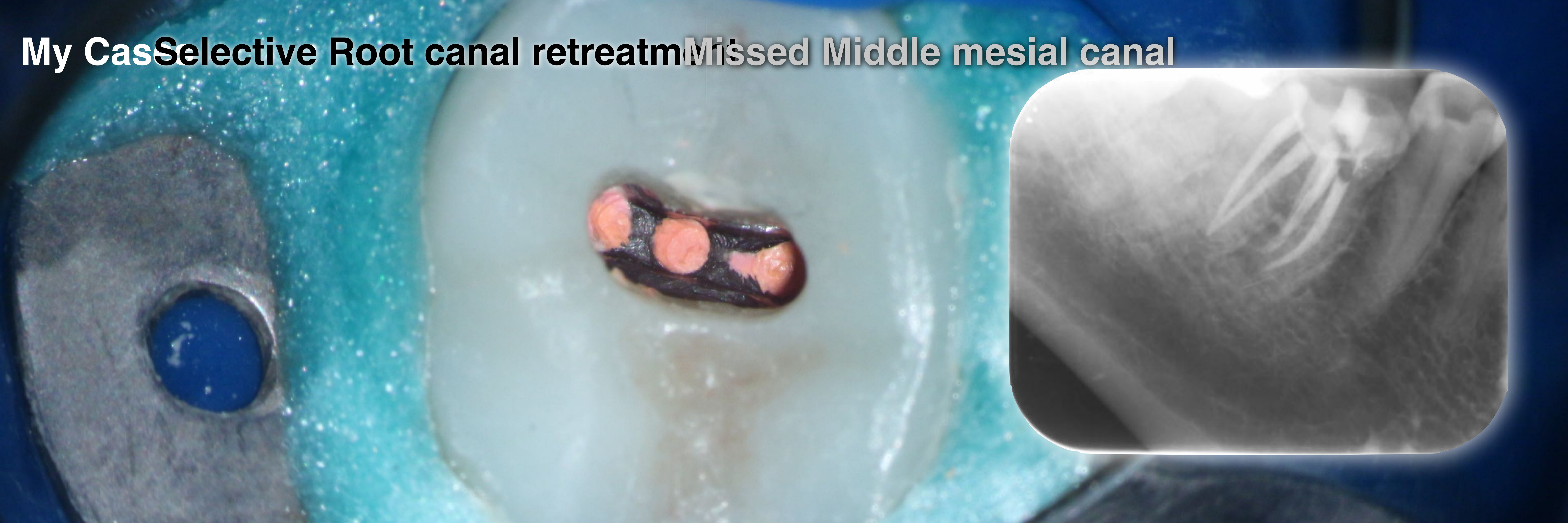

**Follow Up**

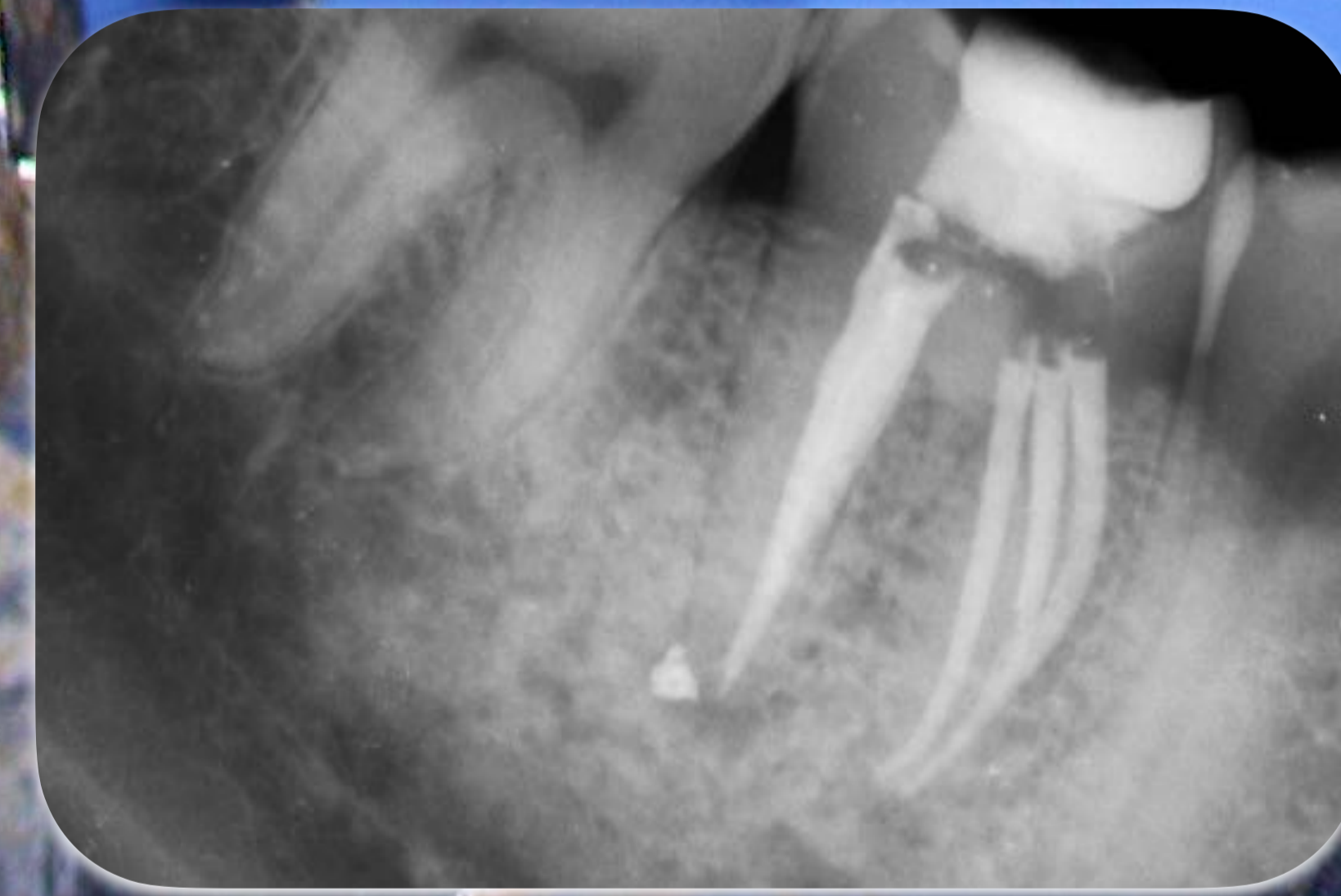4

Difficult Anatomies

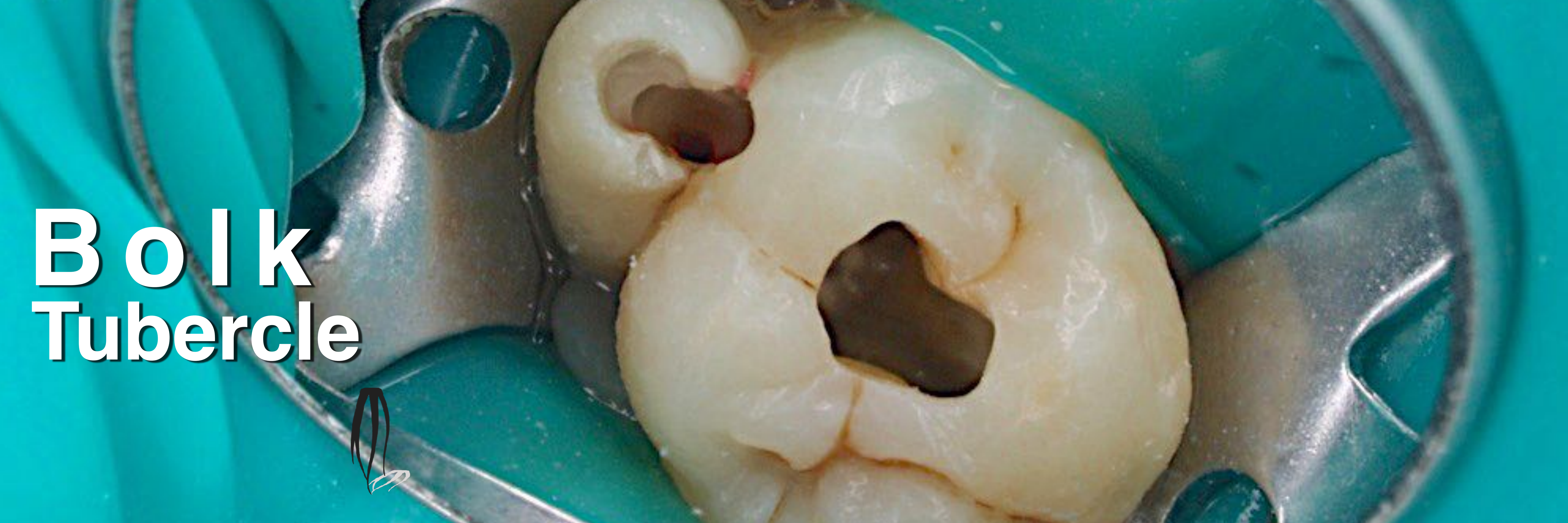# My Case Selective Root canal retreatment Missed Middle mesial canal

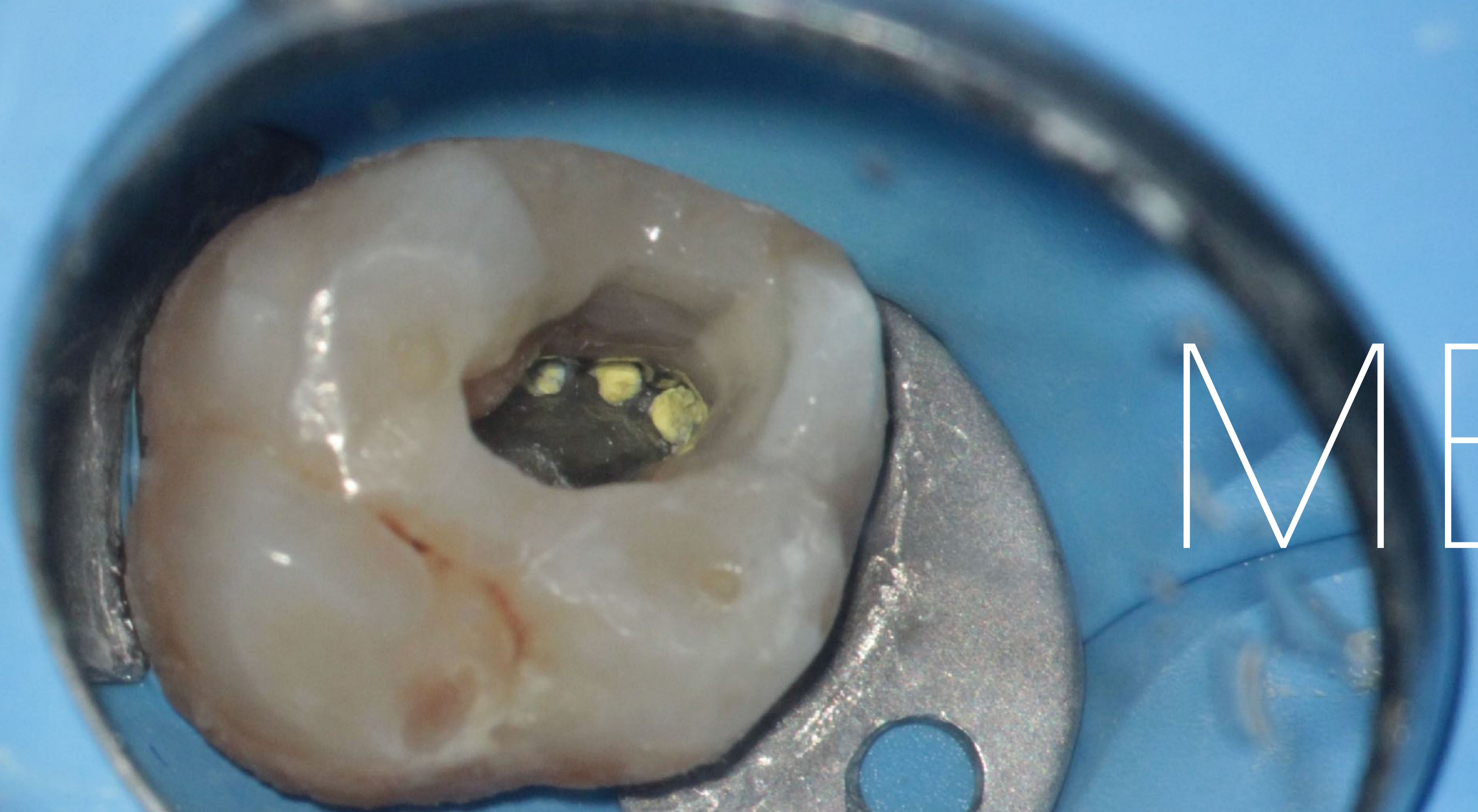


**Missed Middle mesial canal**

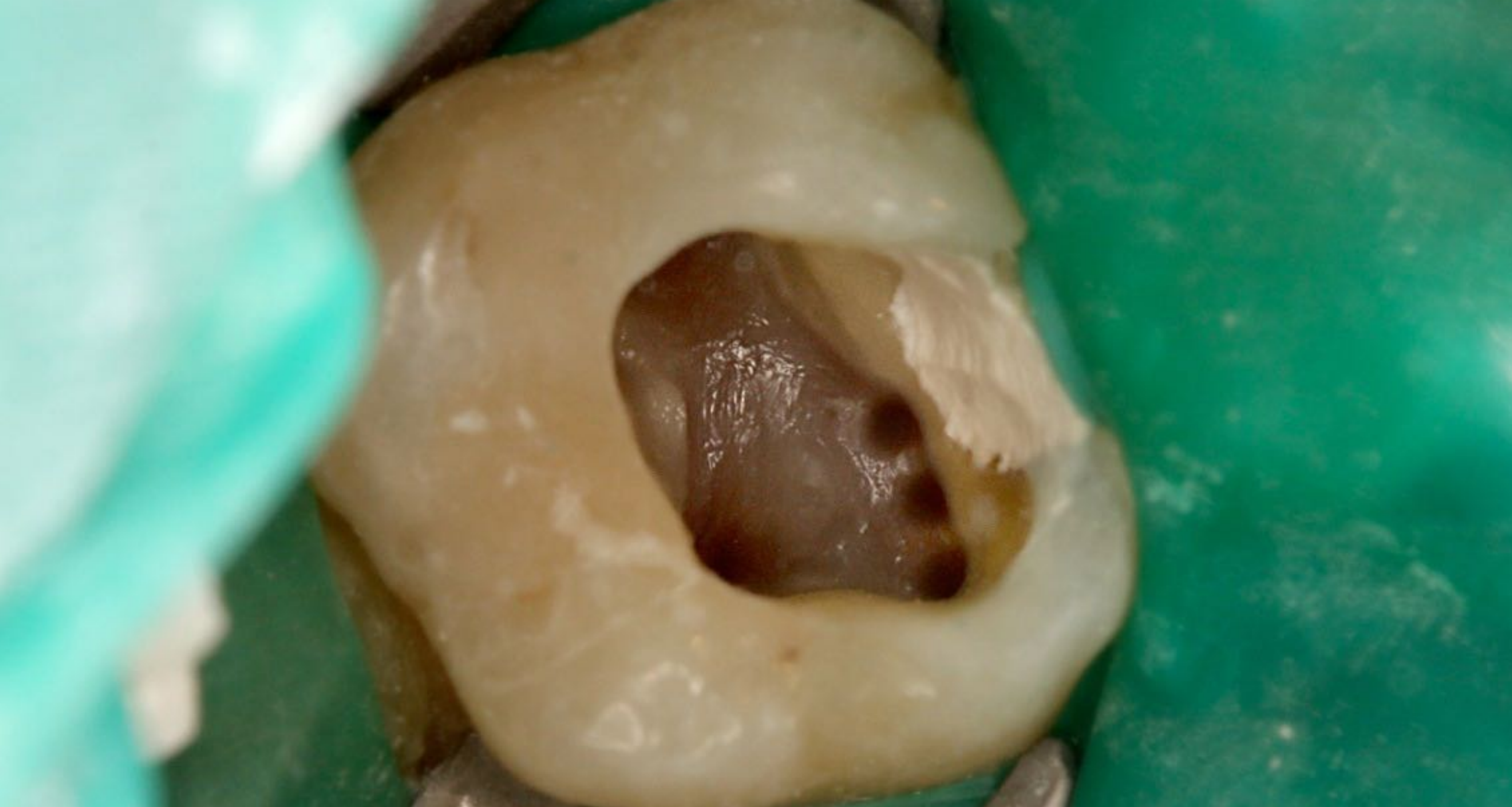

# Boilk Tubercle

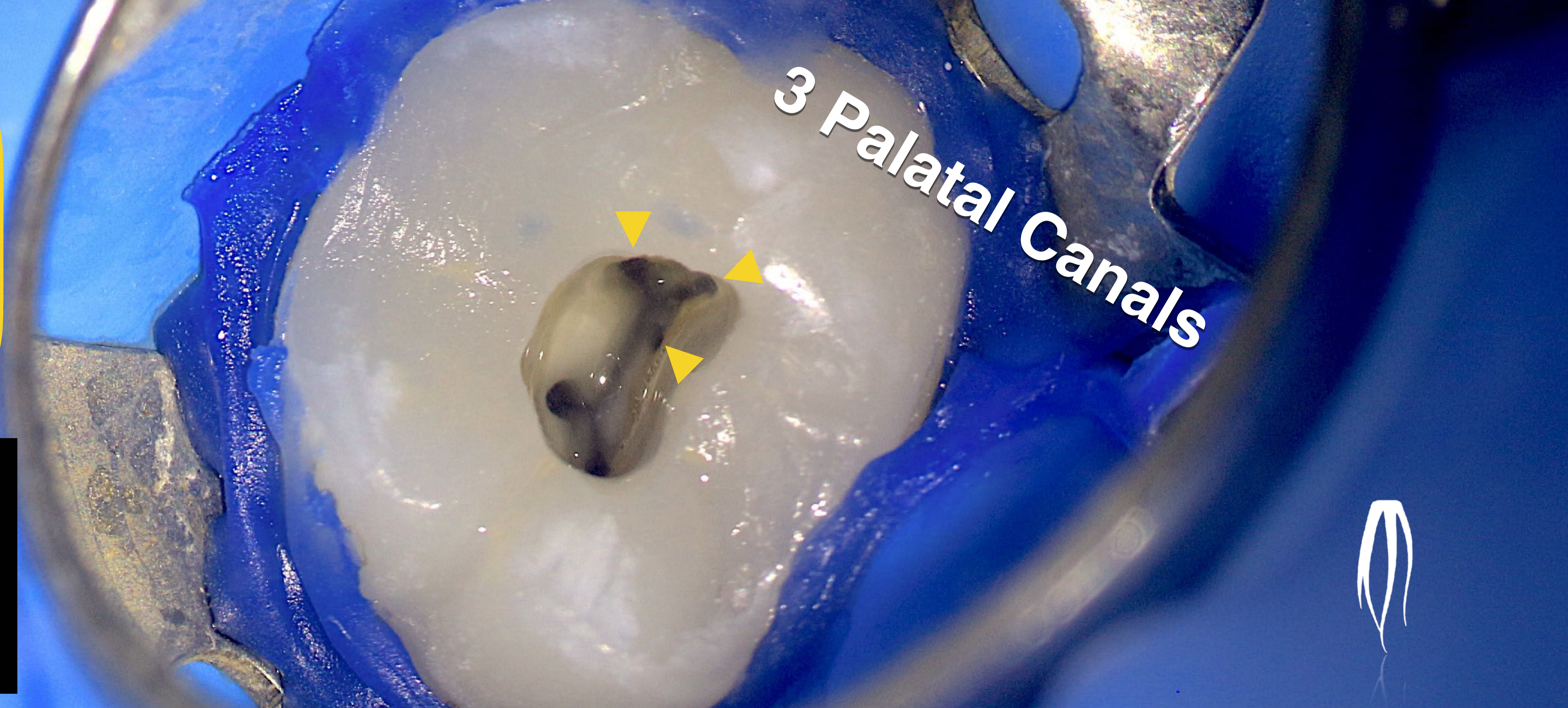
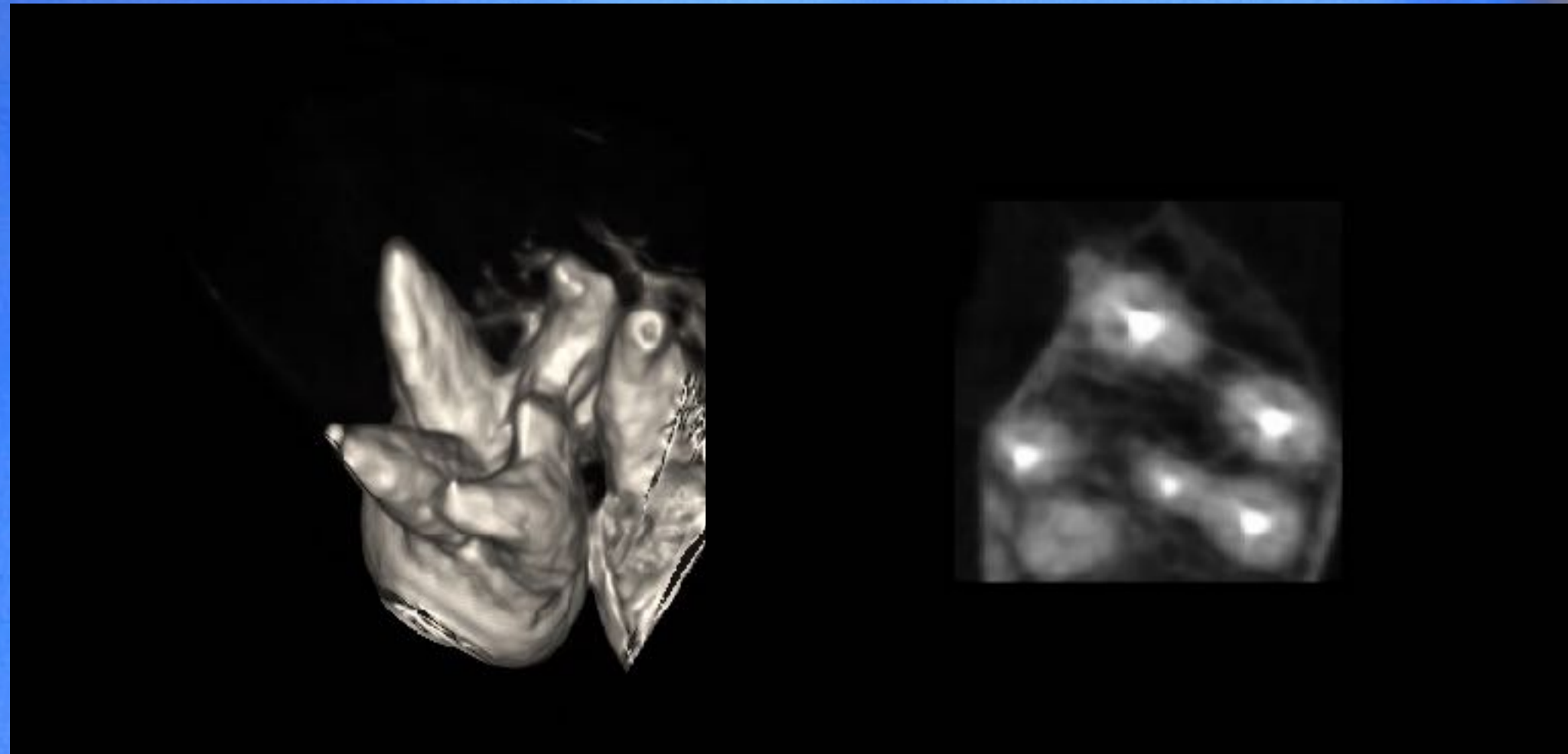
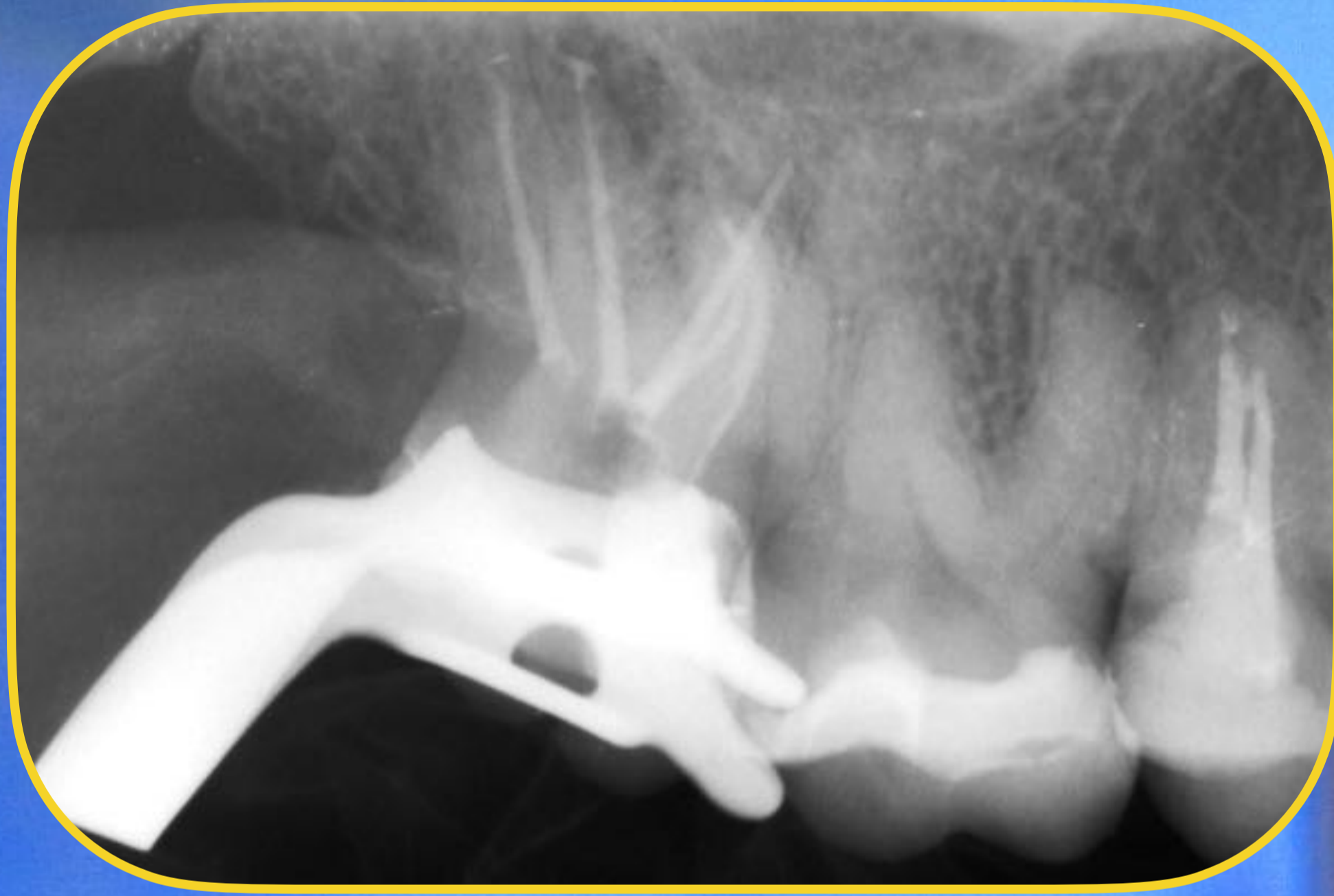




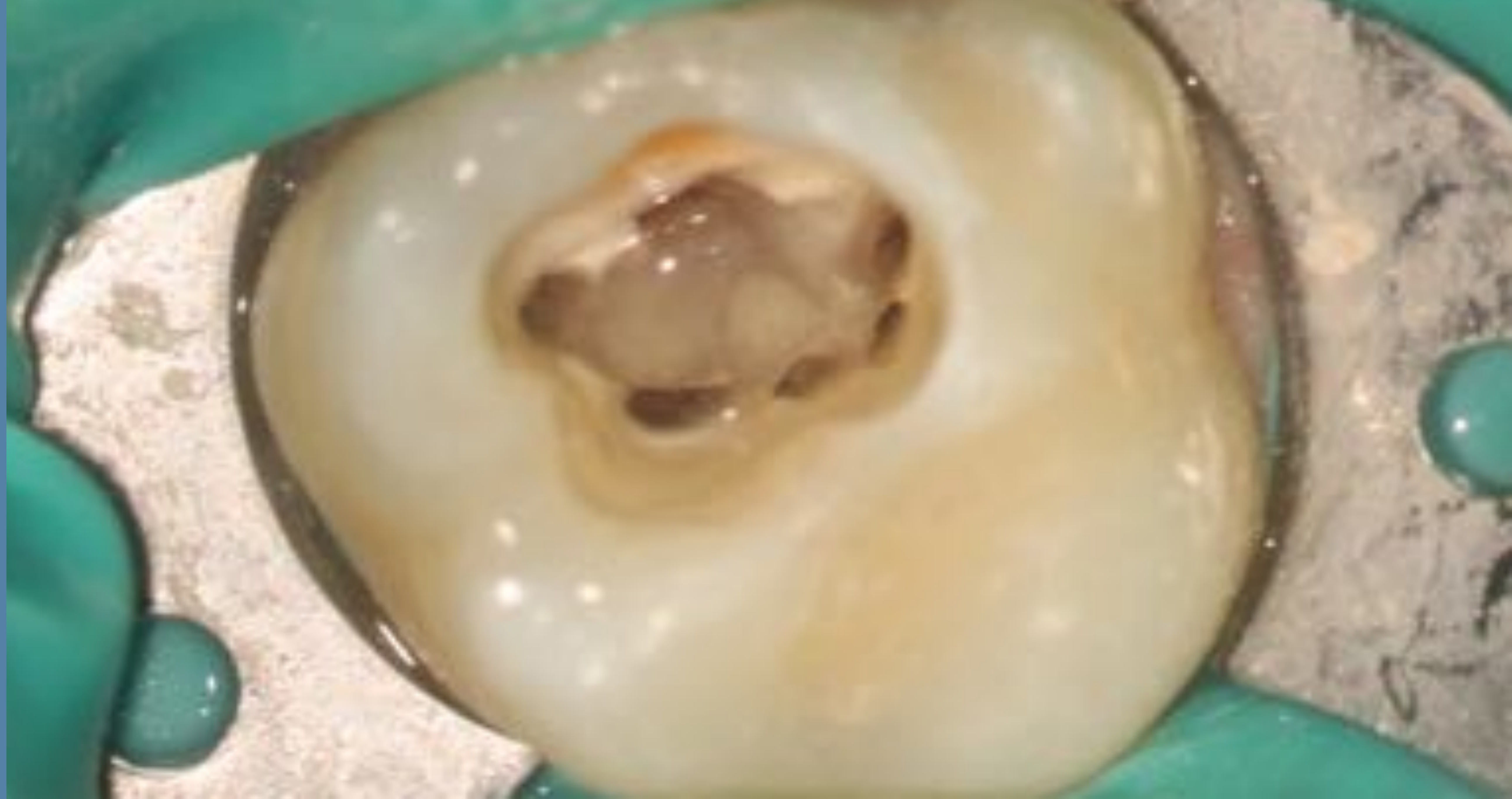MB3



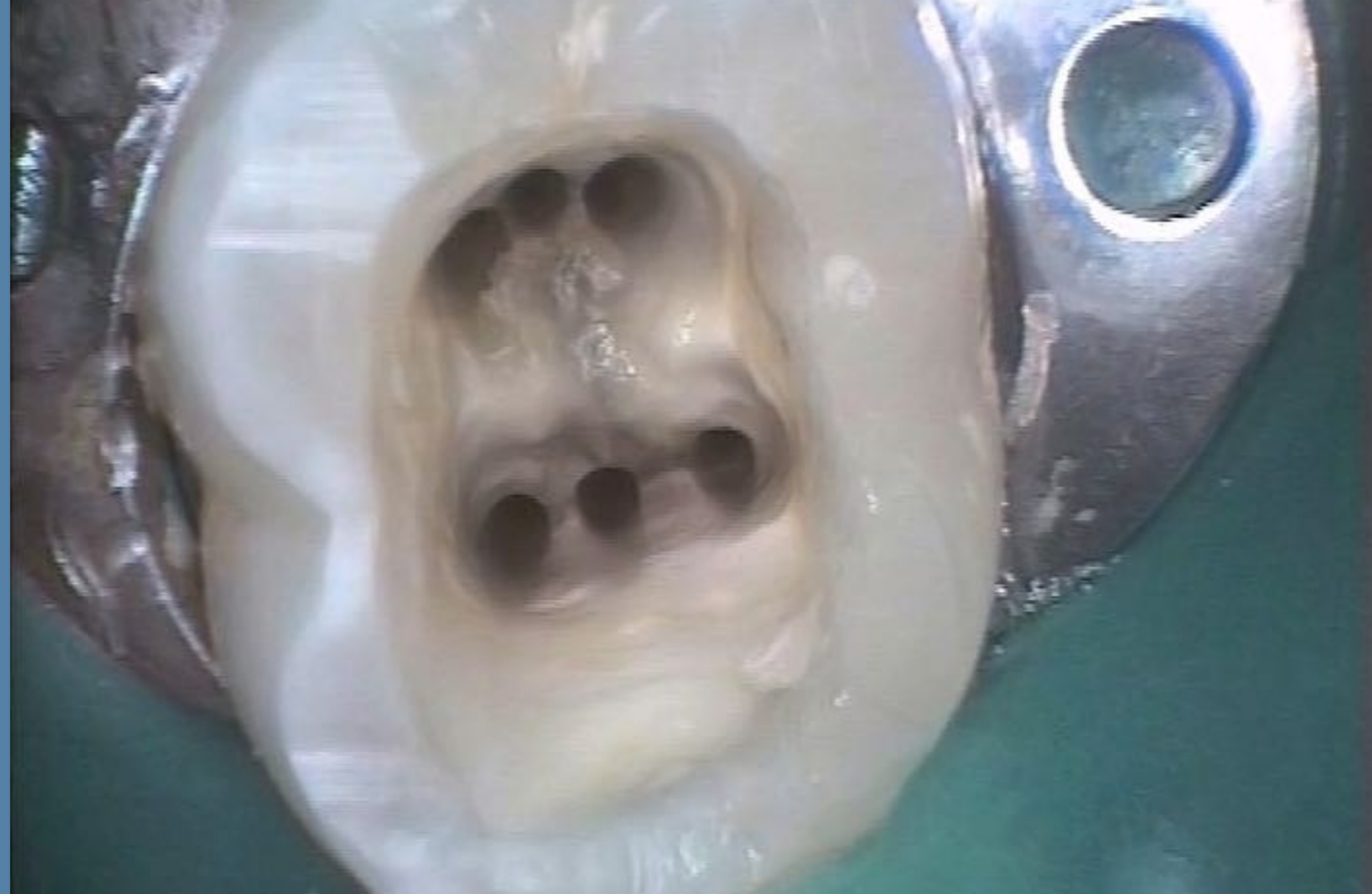MB3



6 Canals Upper Molar



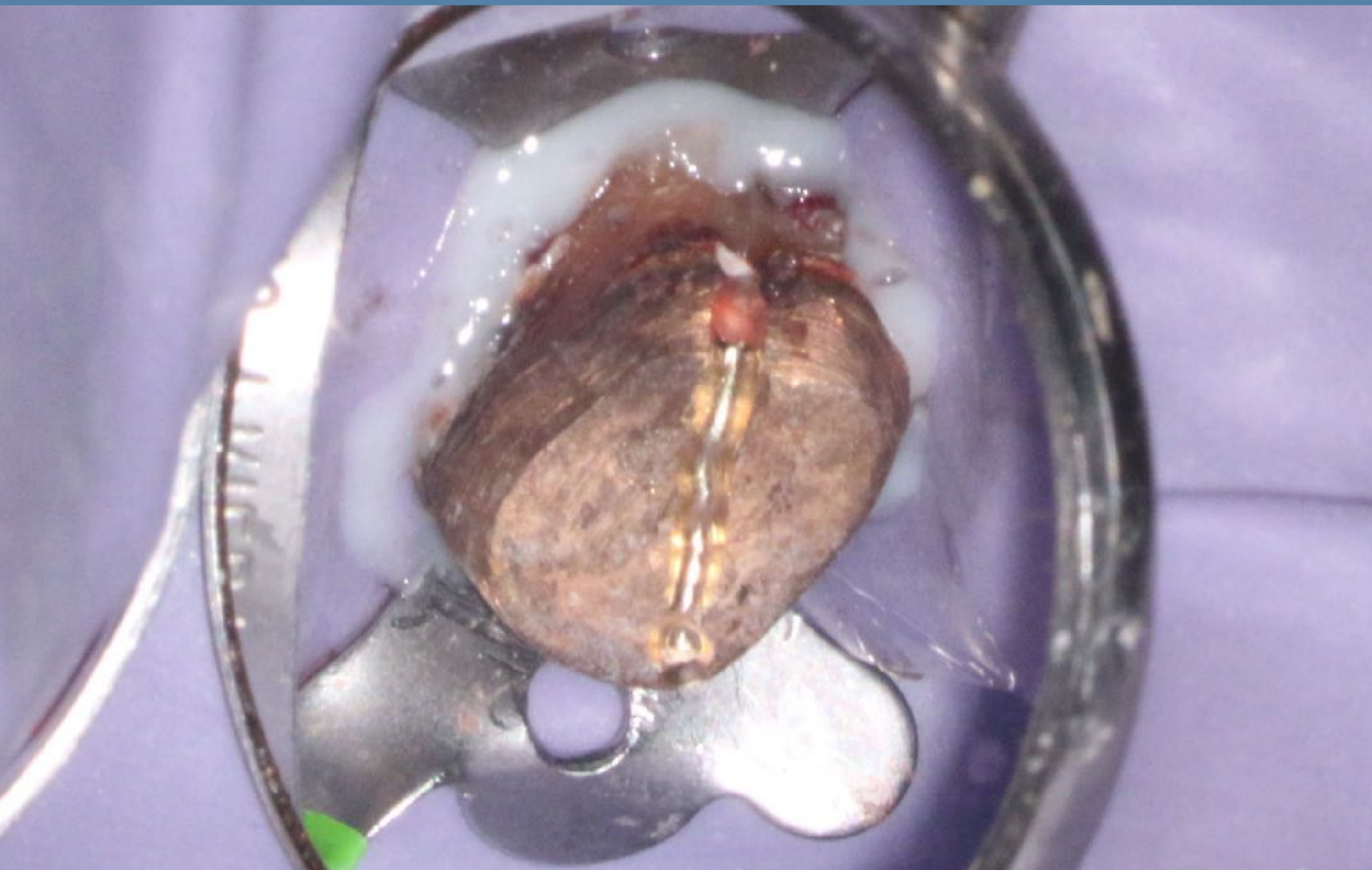
6 Canals Lower Molar



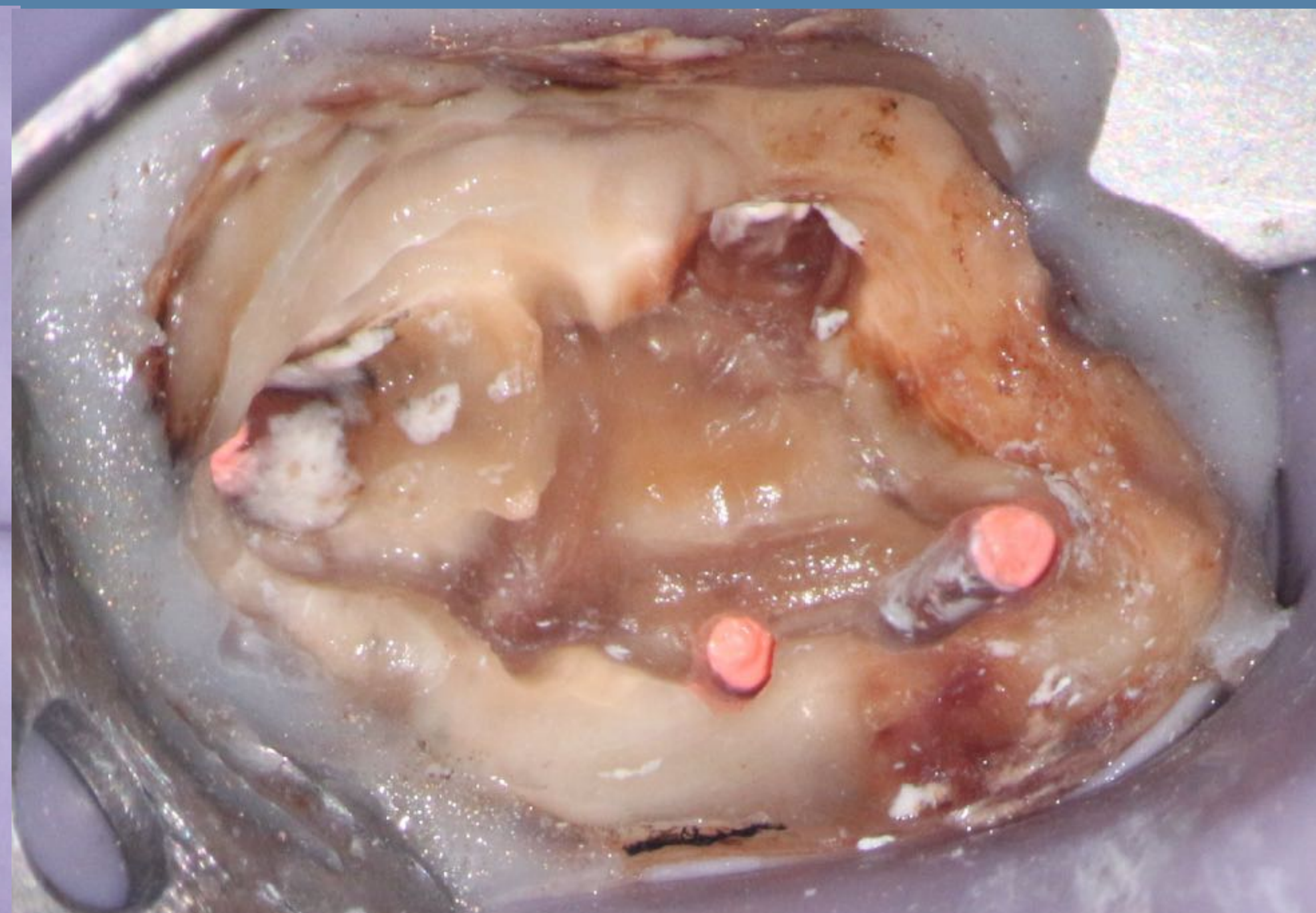
5

Cast post Removal

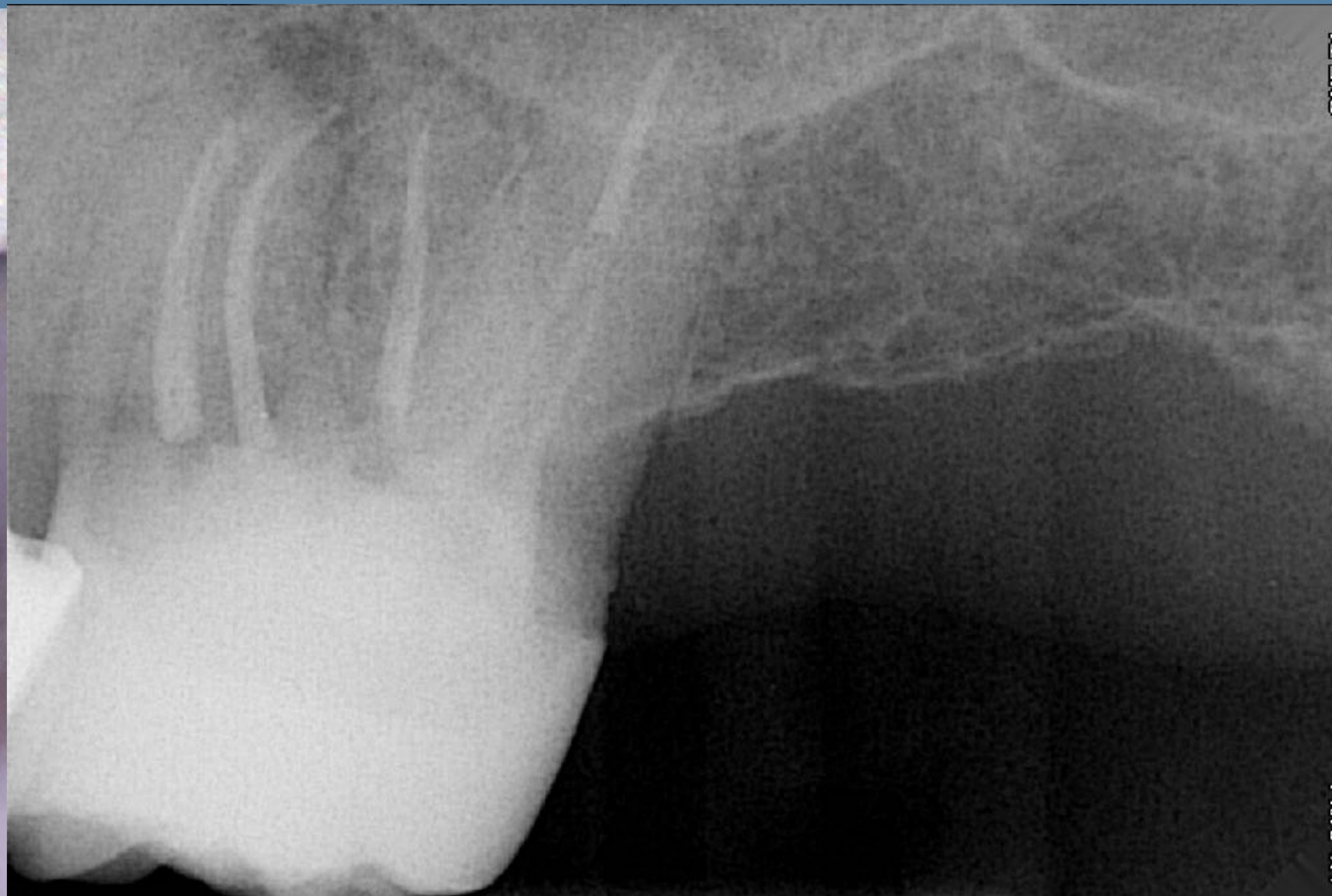
# My Case Cast post Removal



Cast Post



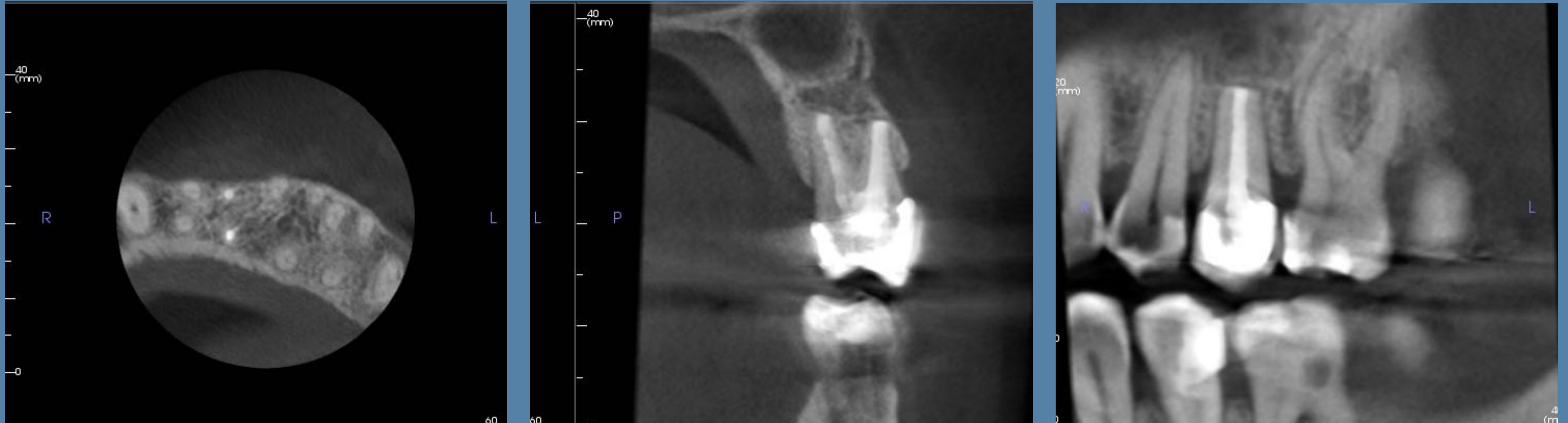Missed Mb2 Treated



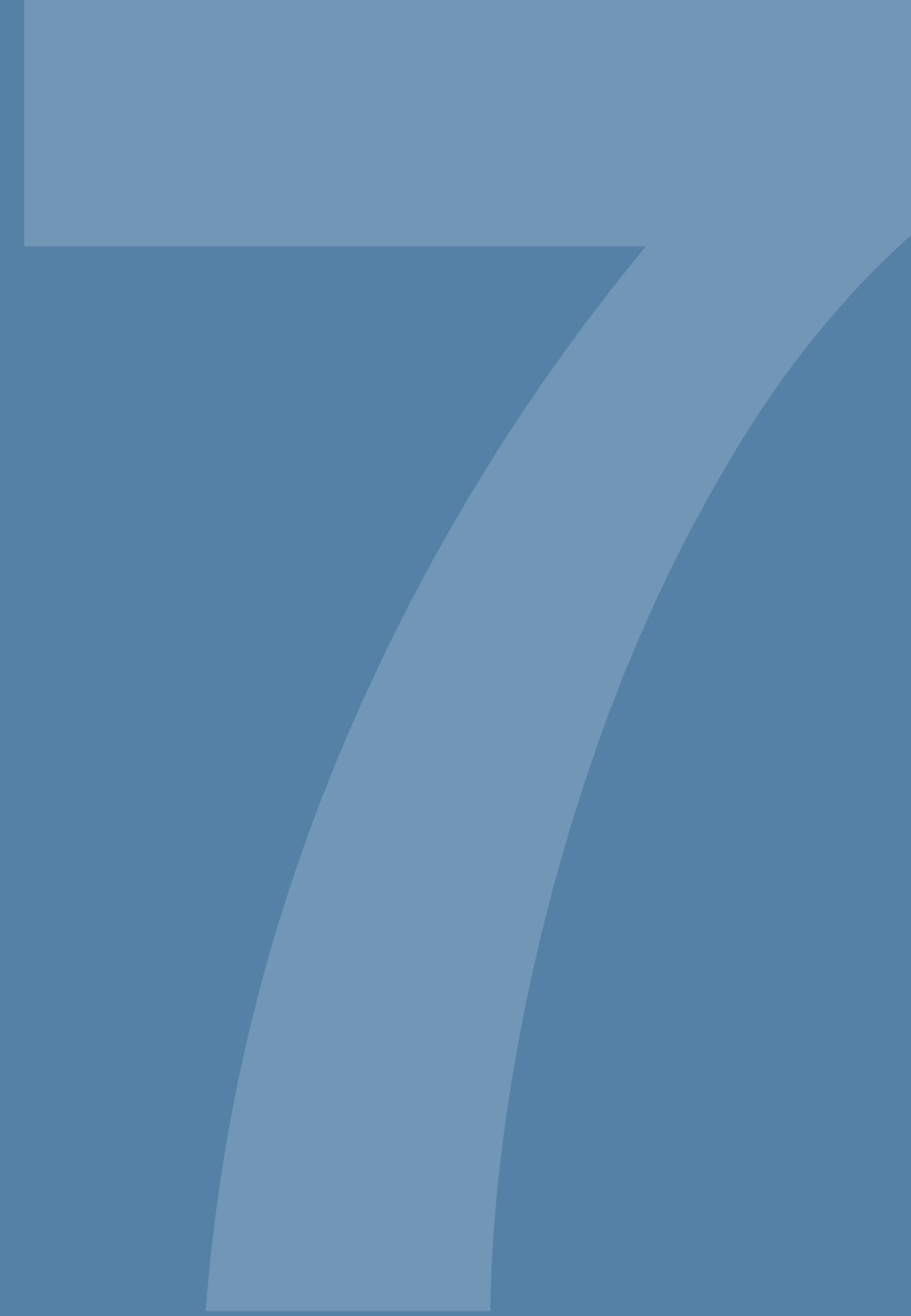Final Retreatment

6

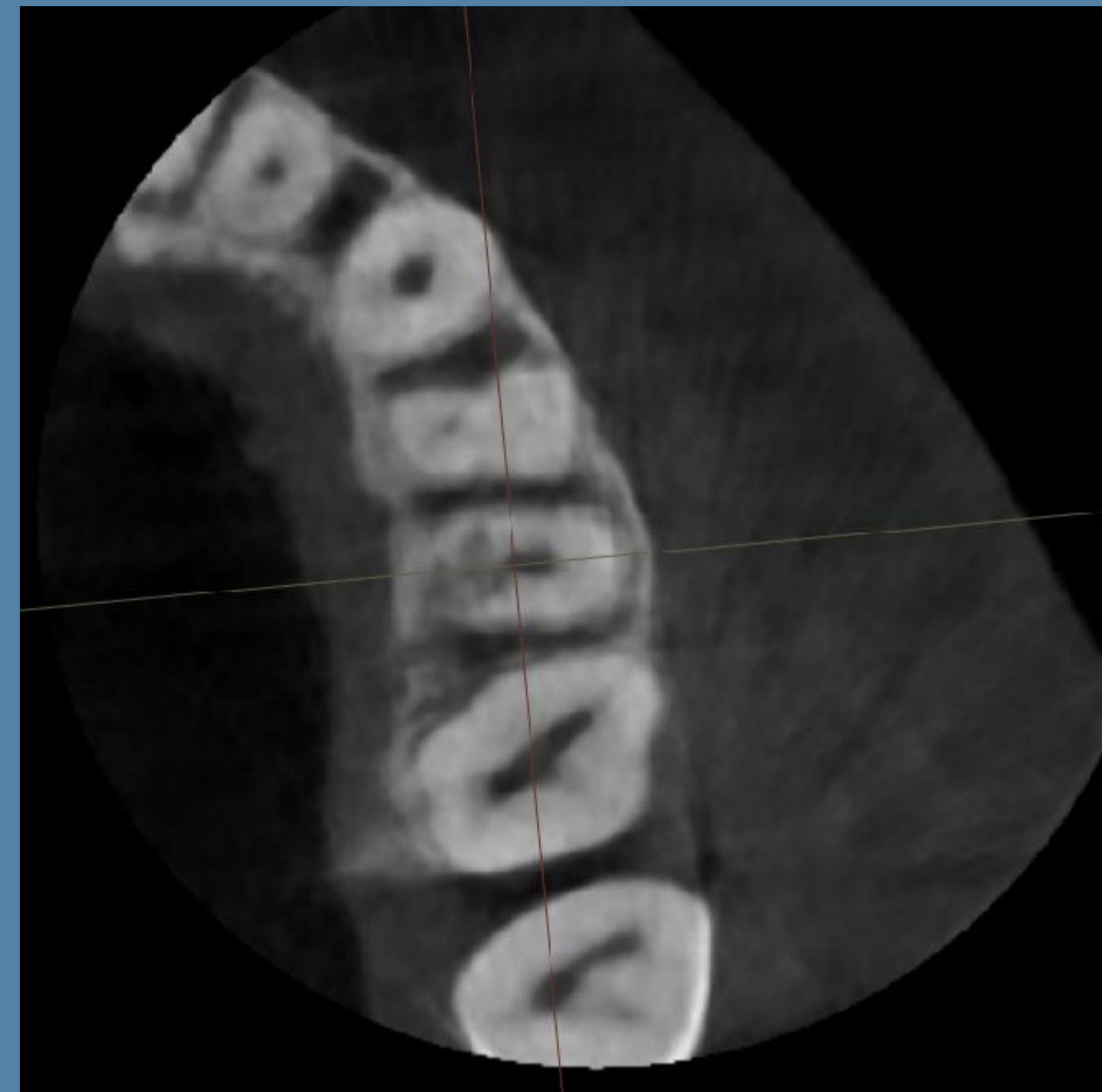Apicoectomy



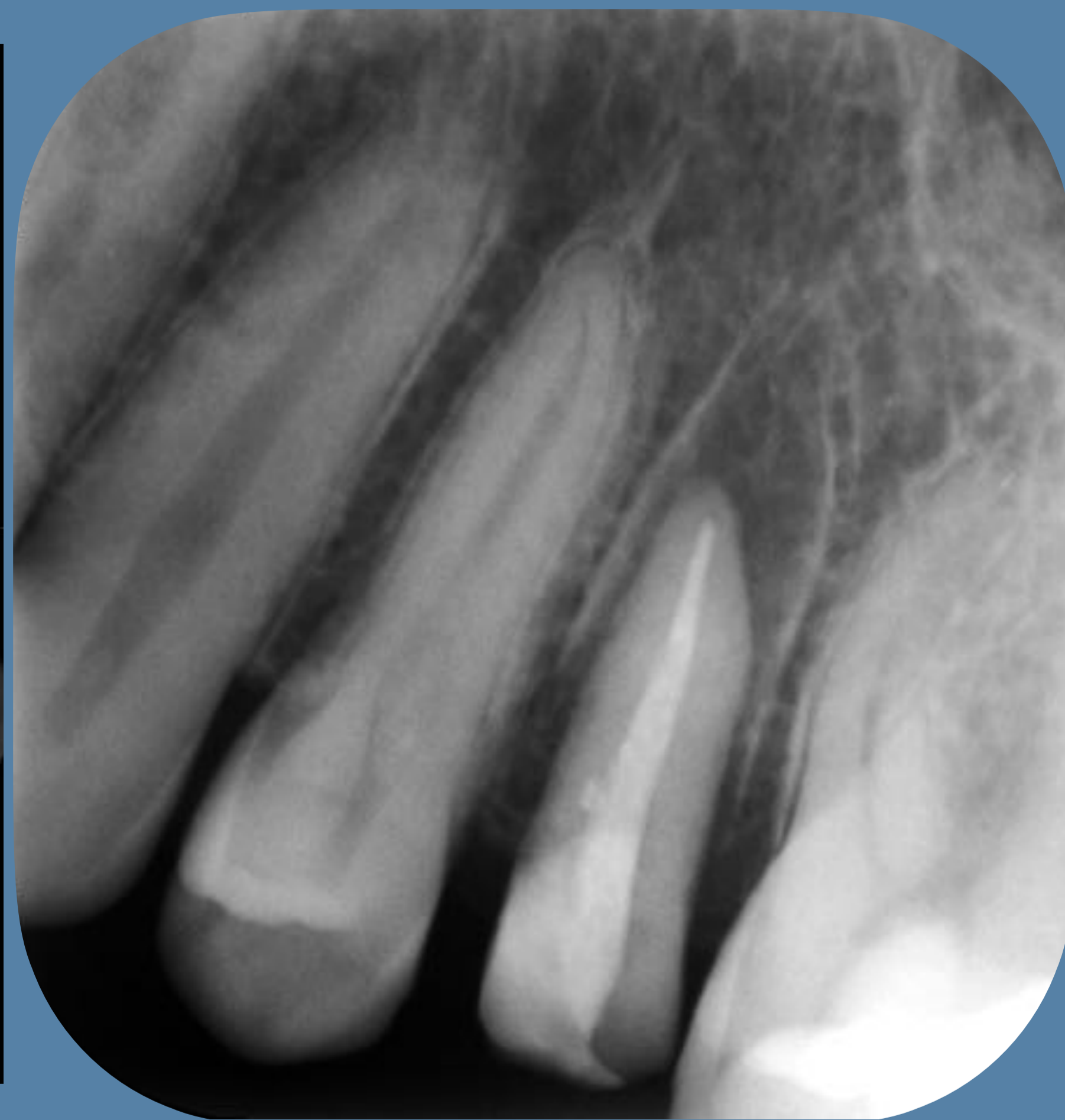
**Apicoectomy buccal and palatal root. 6 Months follow up ,CBCT shows a complete regeneration**



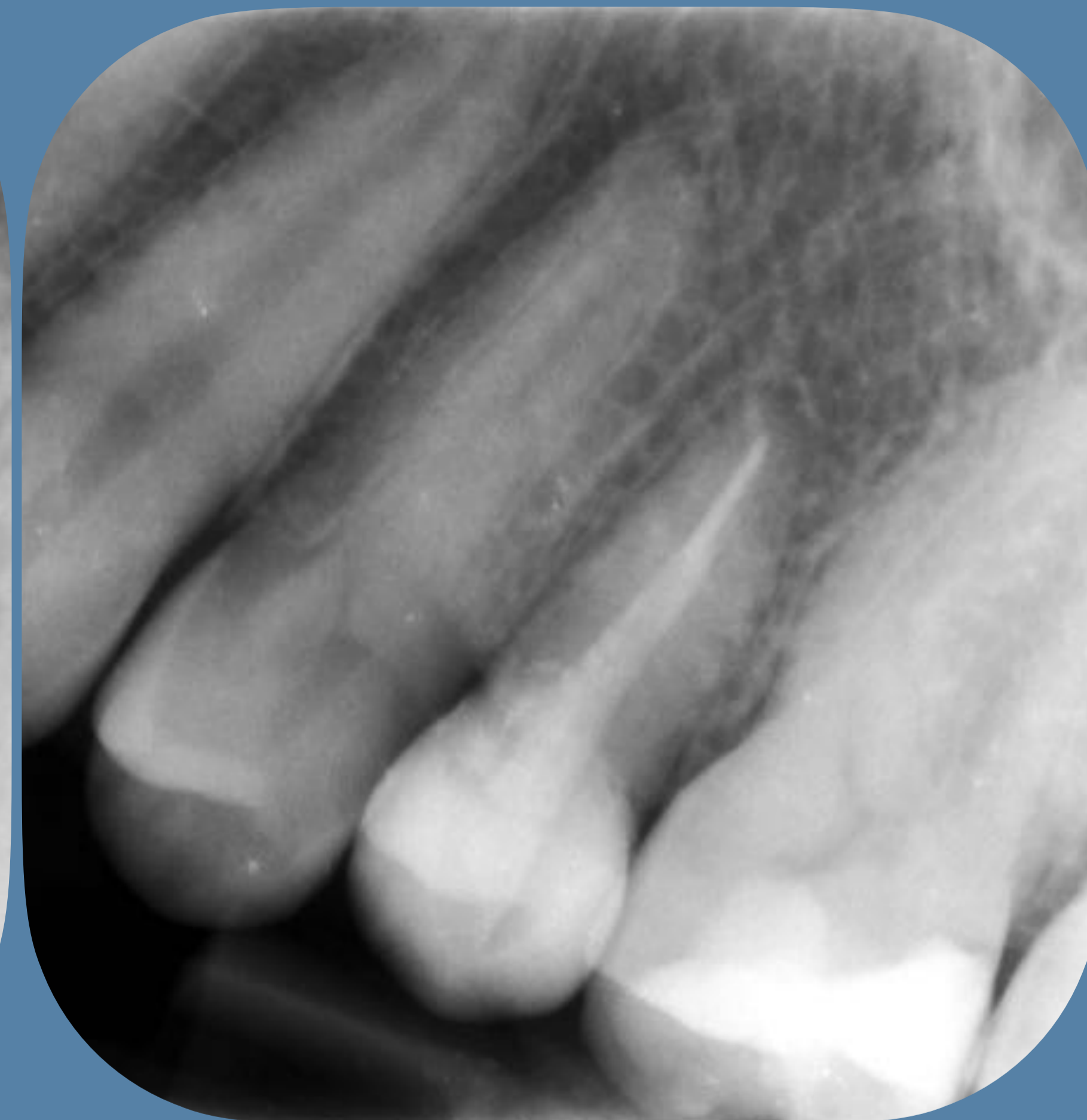
# Tooth Reimplantation



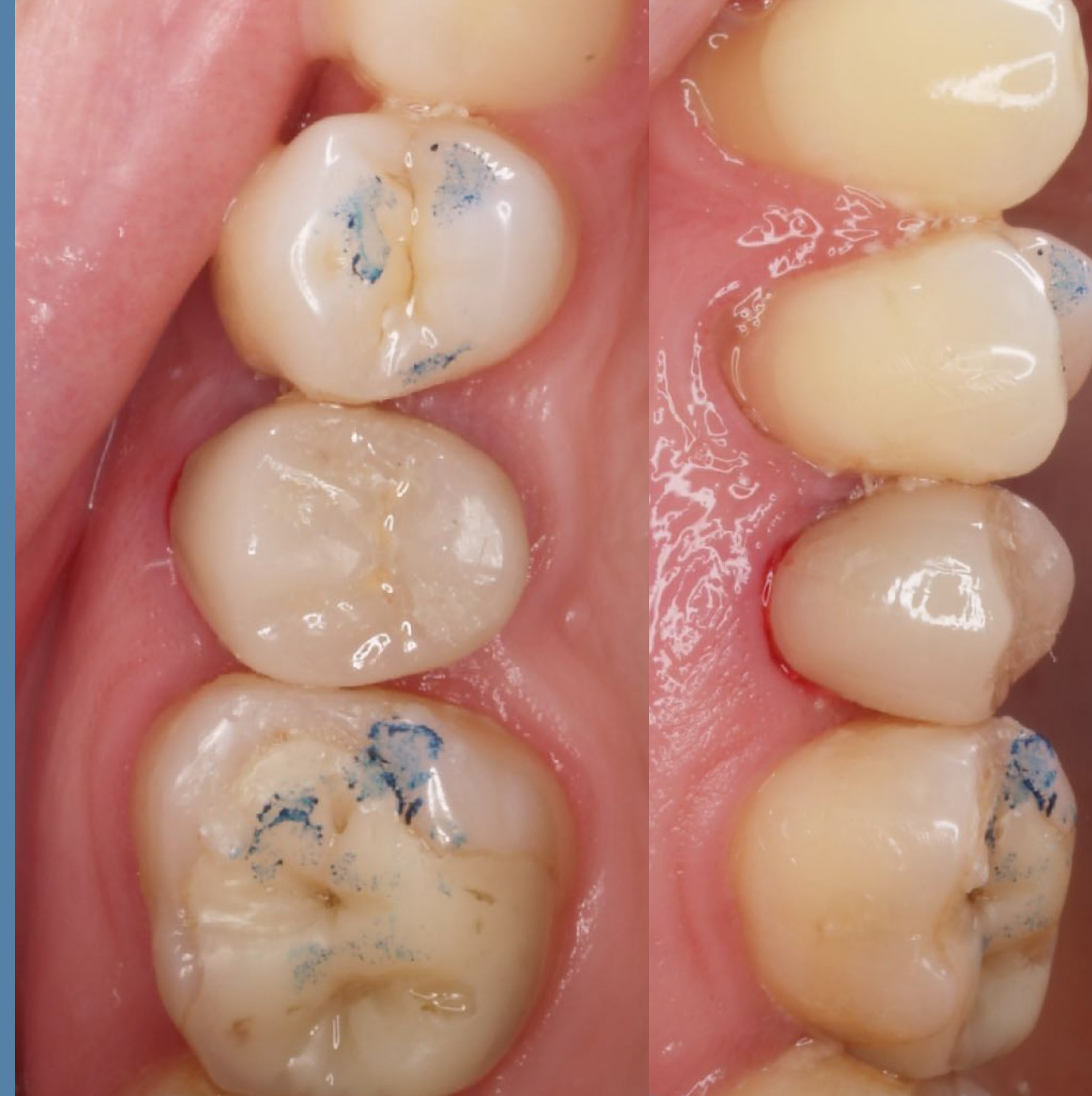**Cervical resorption under the crestal bone level**

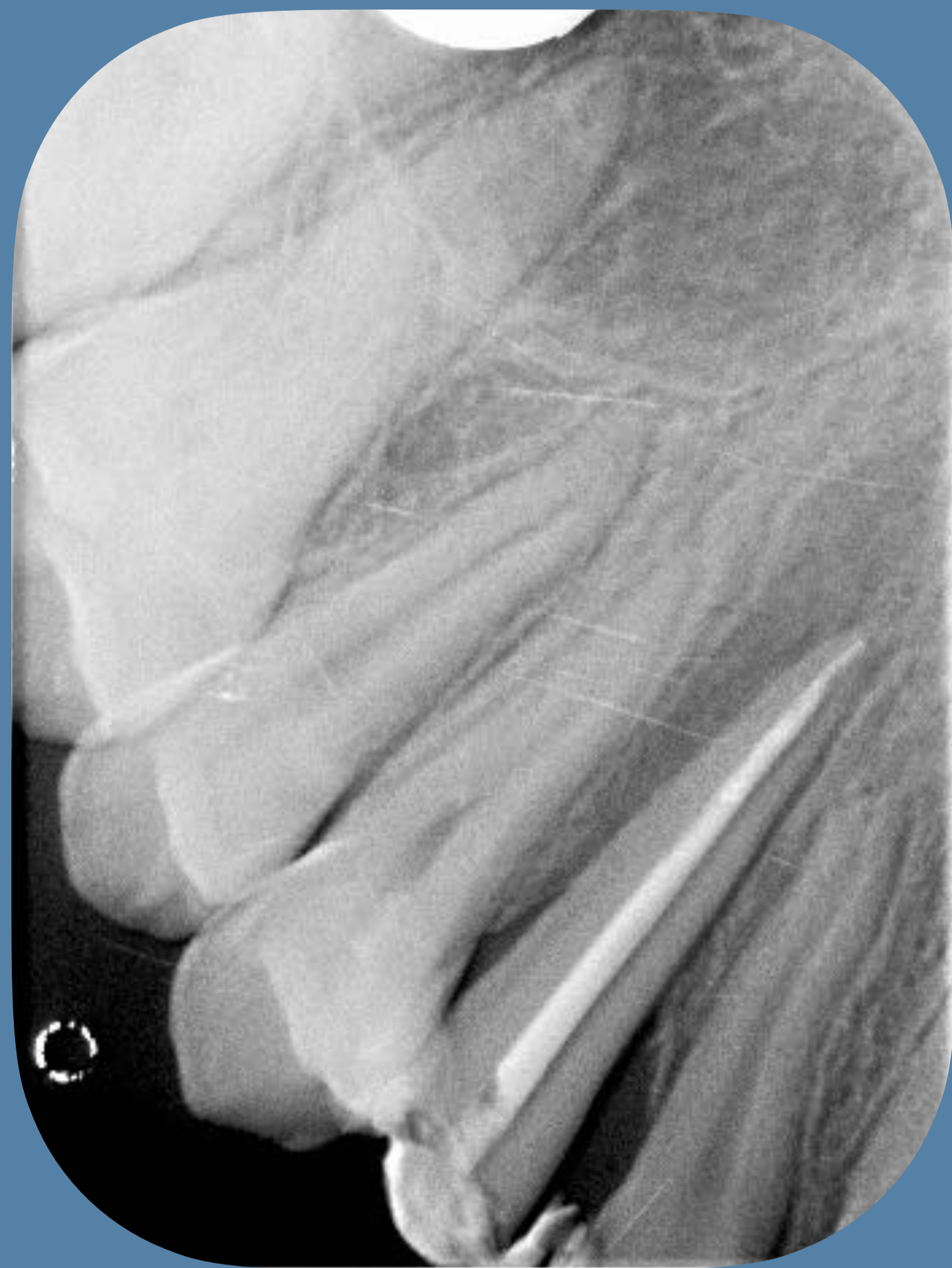

**RCT + Tooth Replantation in a coronal position**

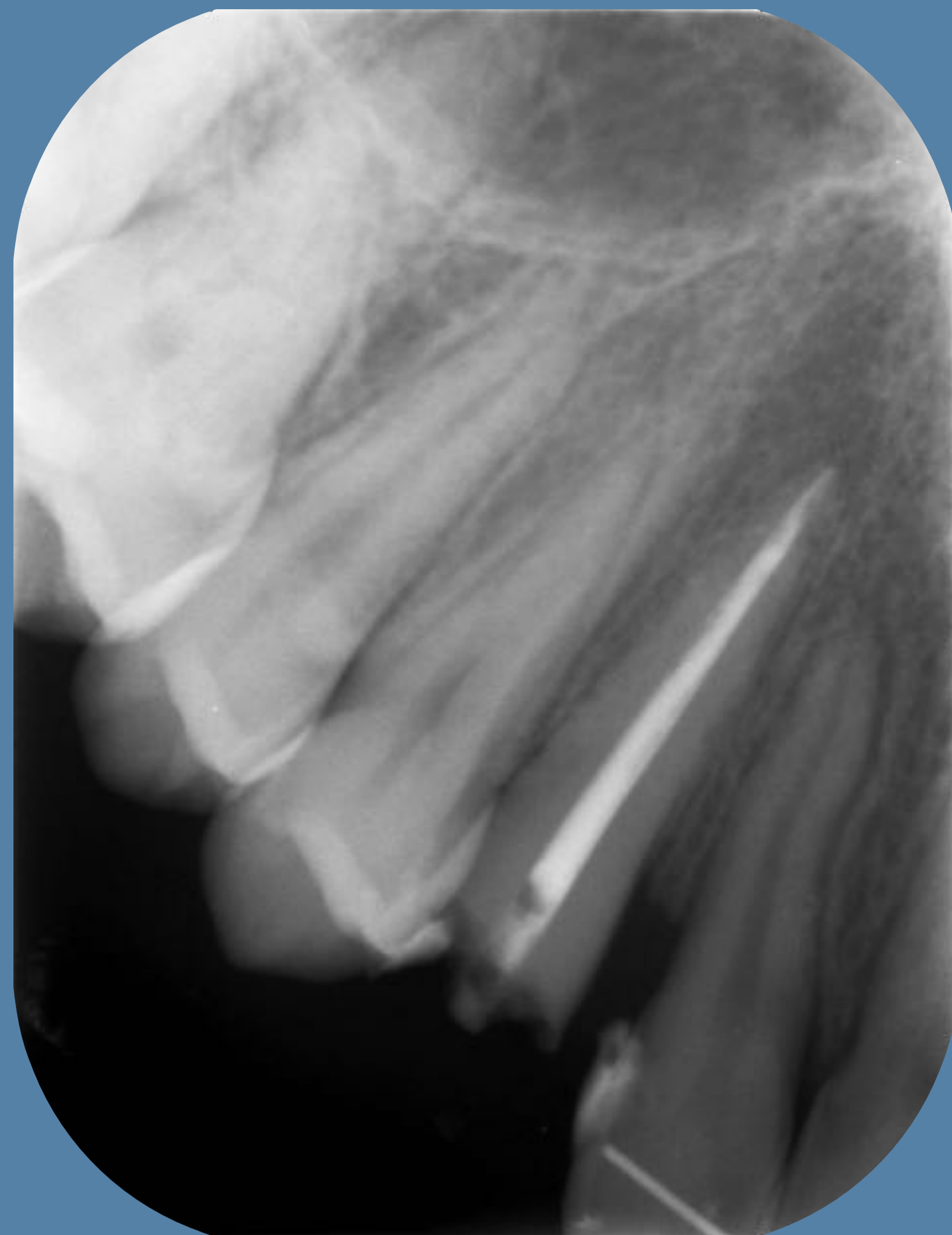

**6 Months Follow up Complete regeneration**

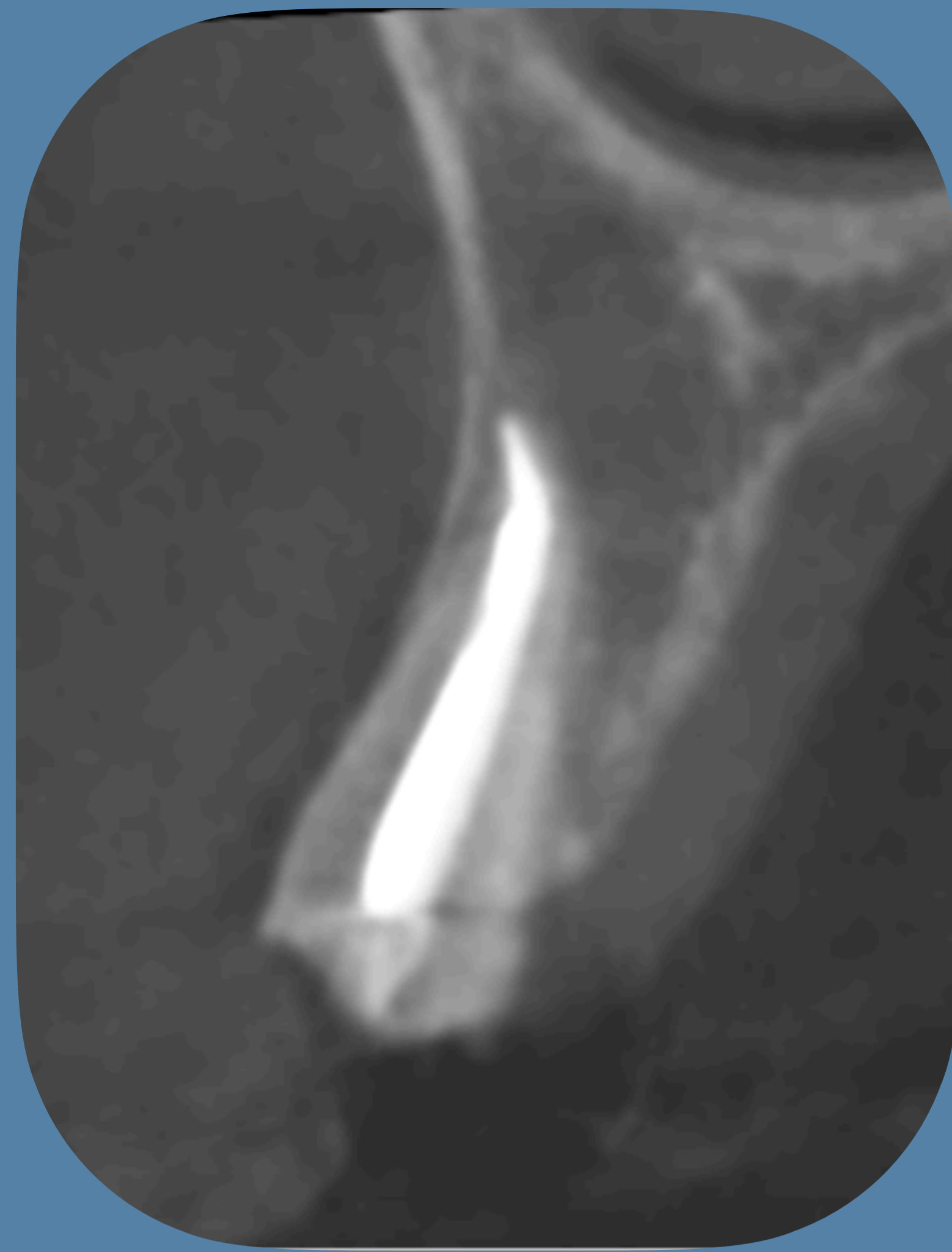




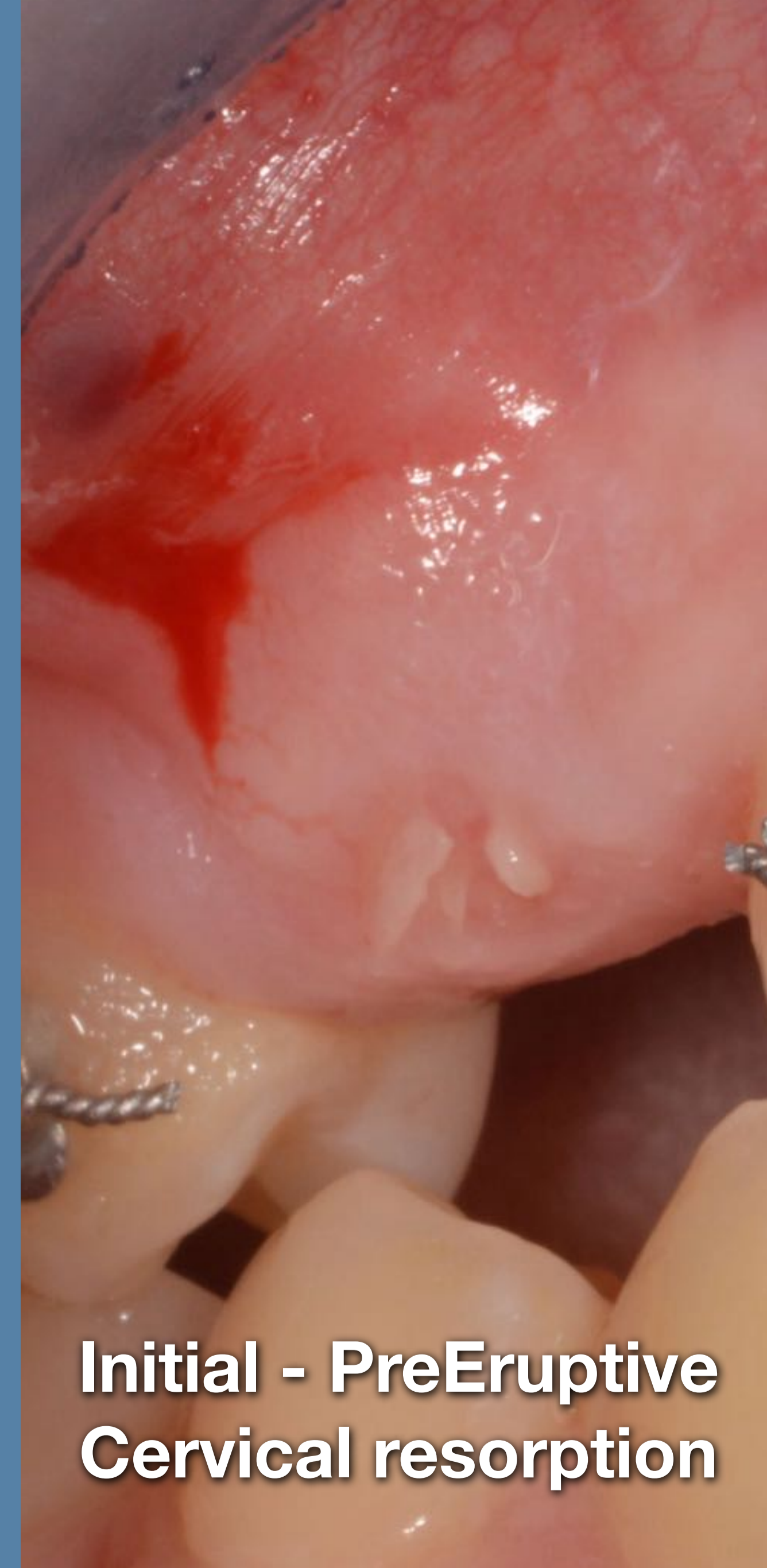**Replantation**



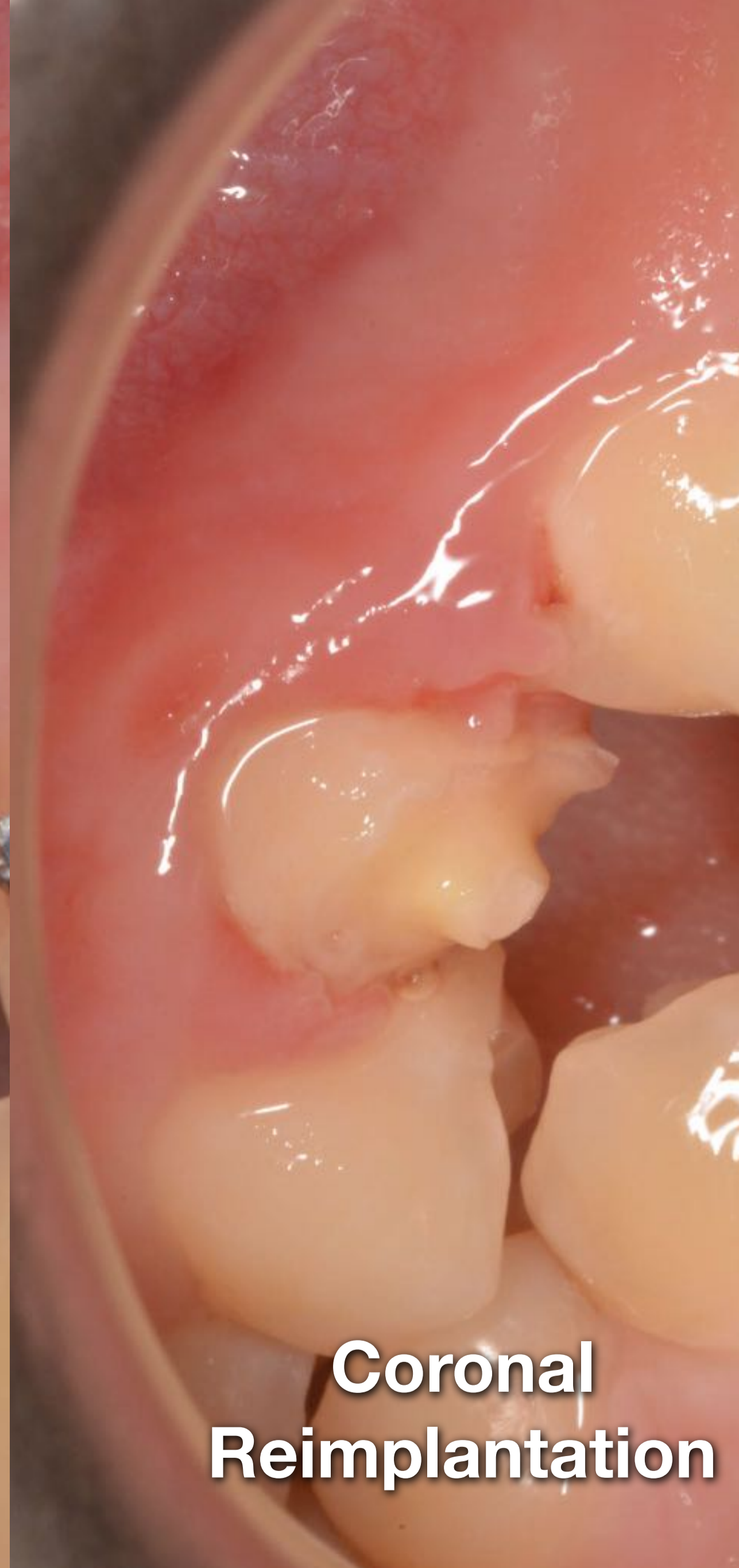
**Follow up  
Complete regeneration**



**CBCT Follow up  
Complete regeneration**



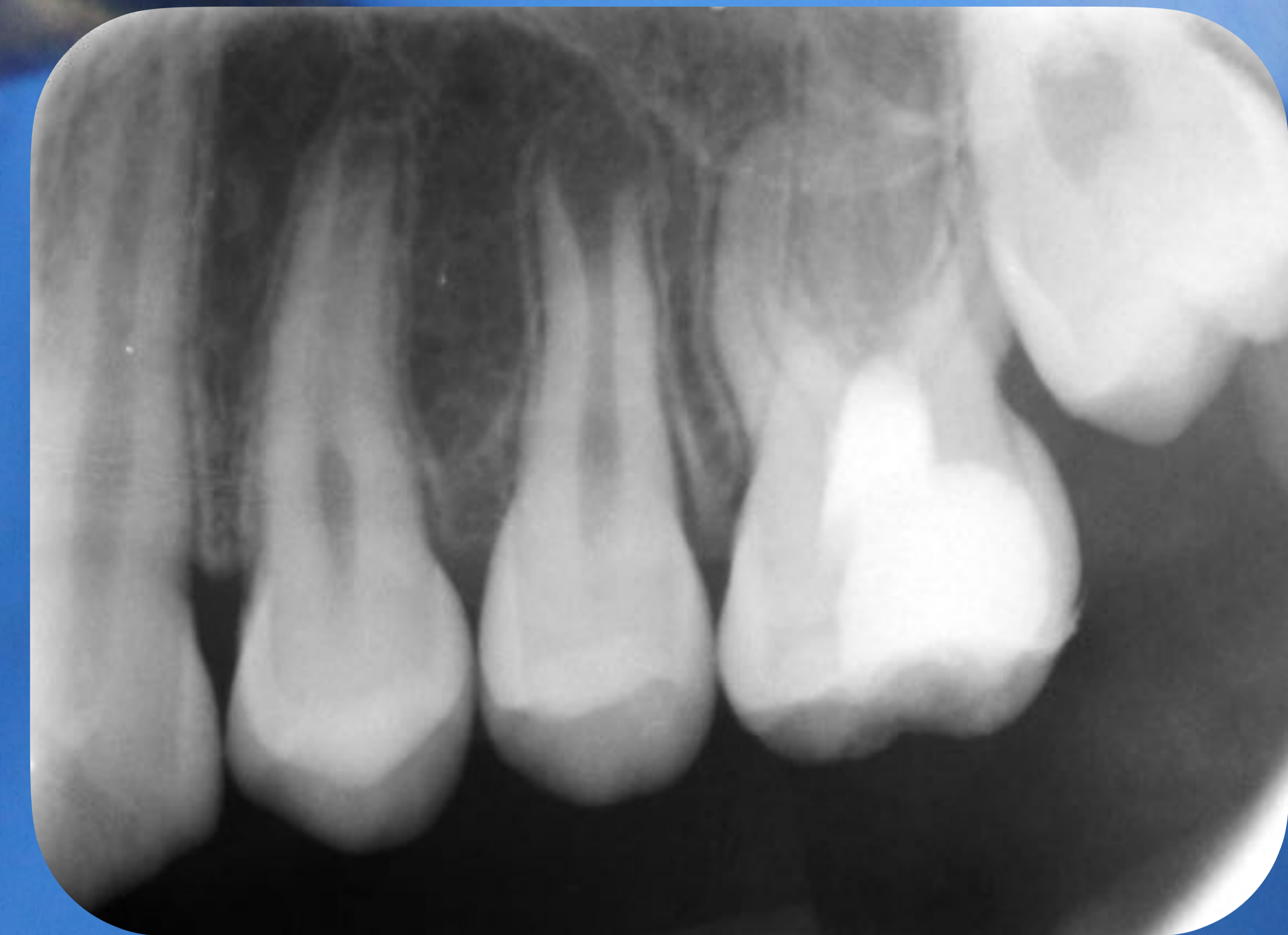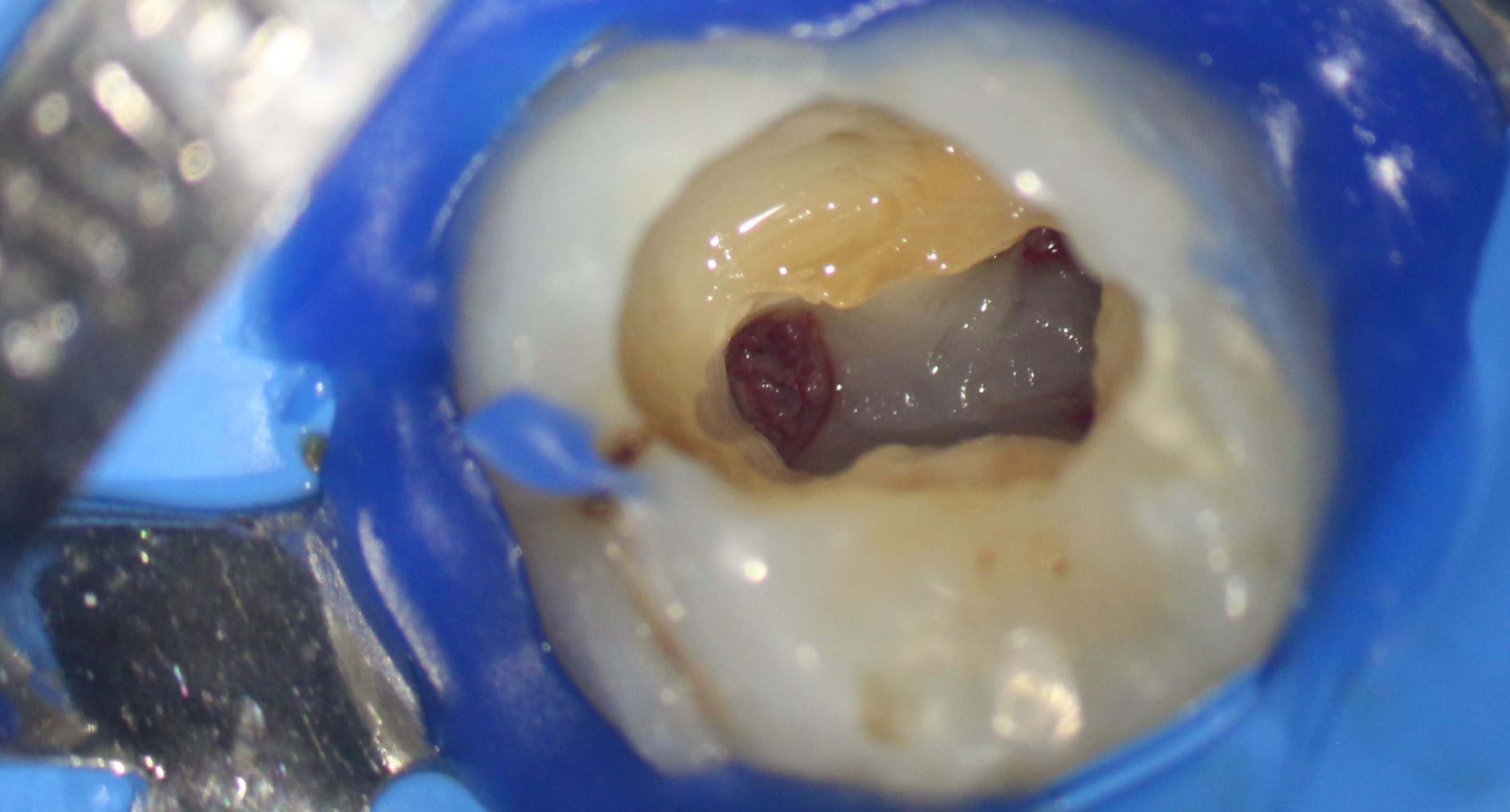
**Initial - PreEruptive  
Cervical resorption**



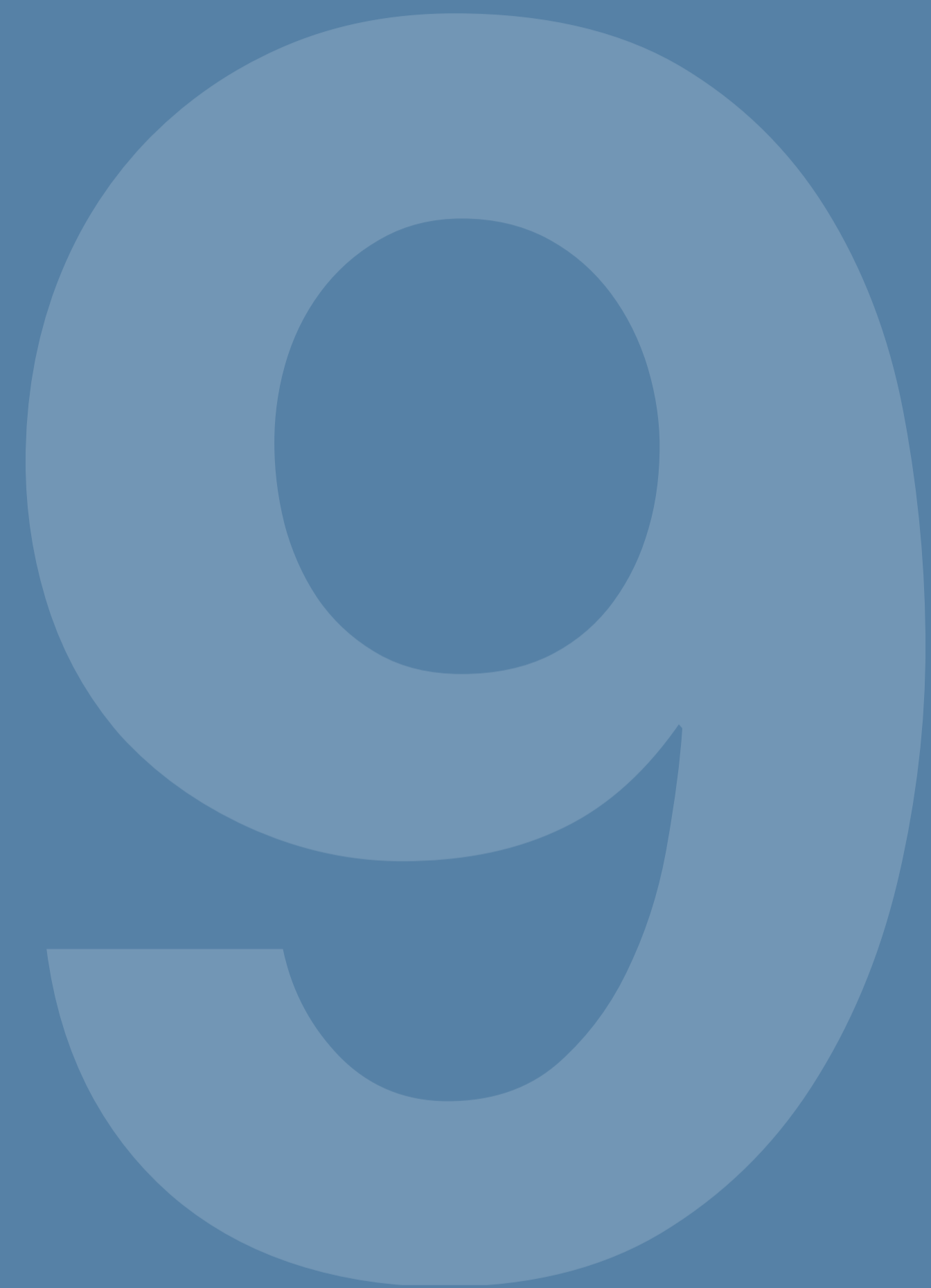**Coronal  
Reimplantation**



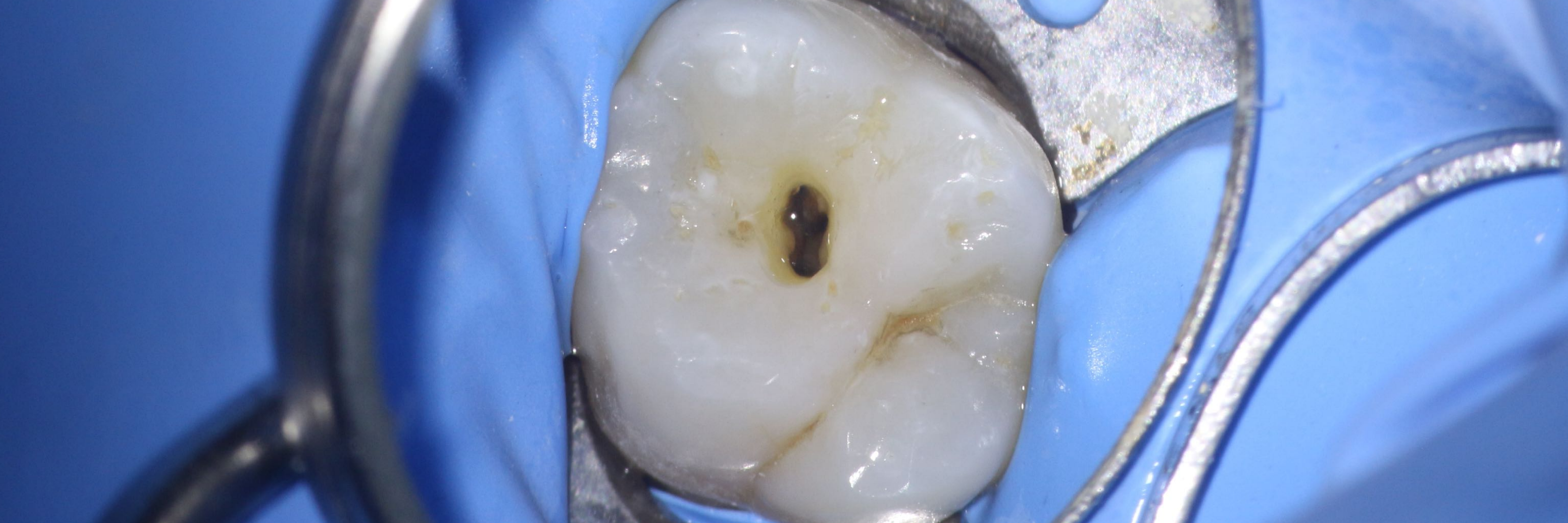# Vital Pulp Therapy

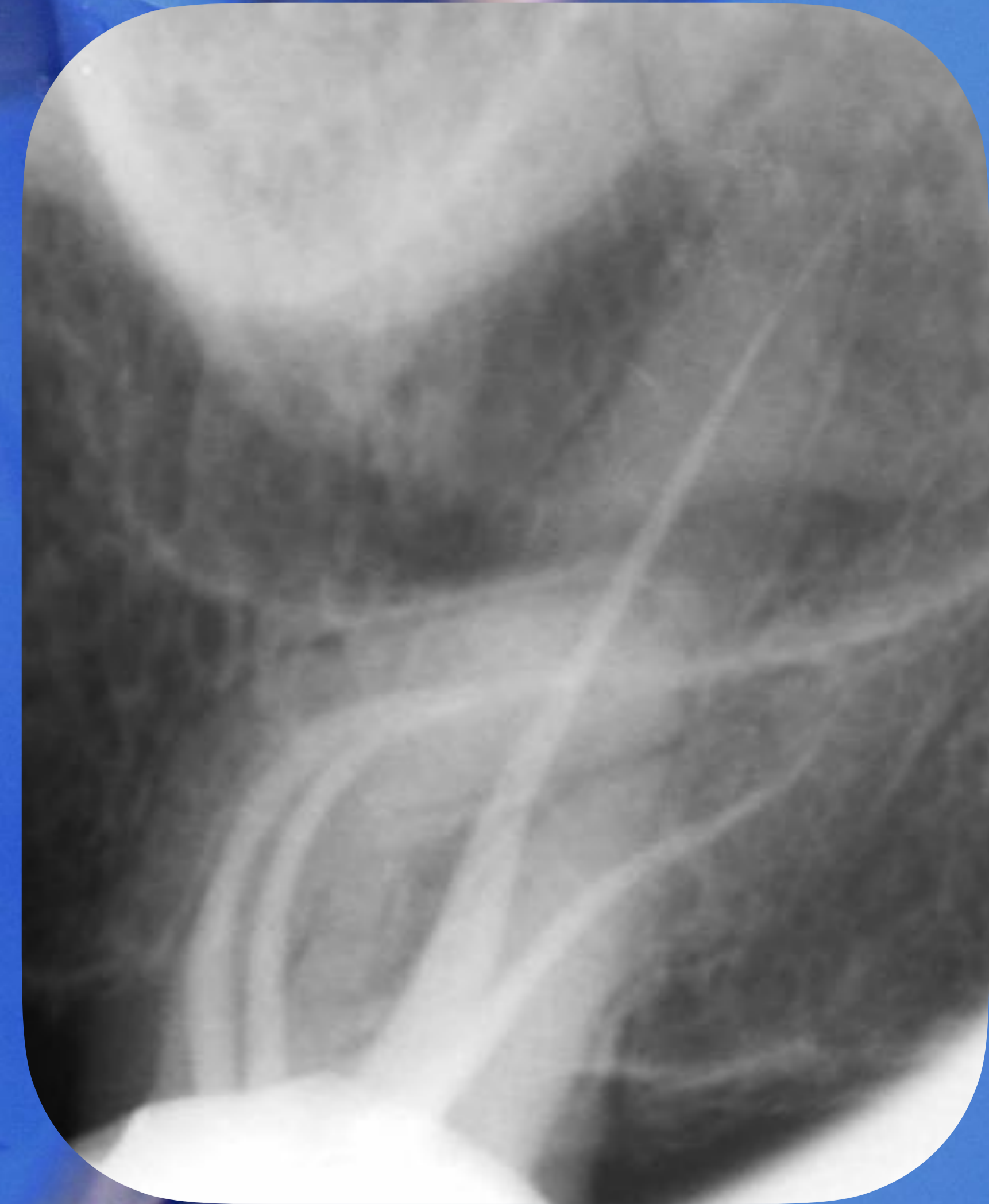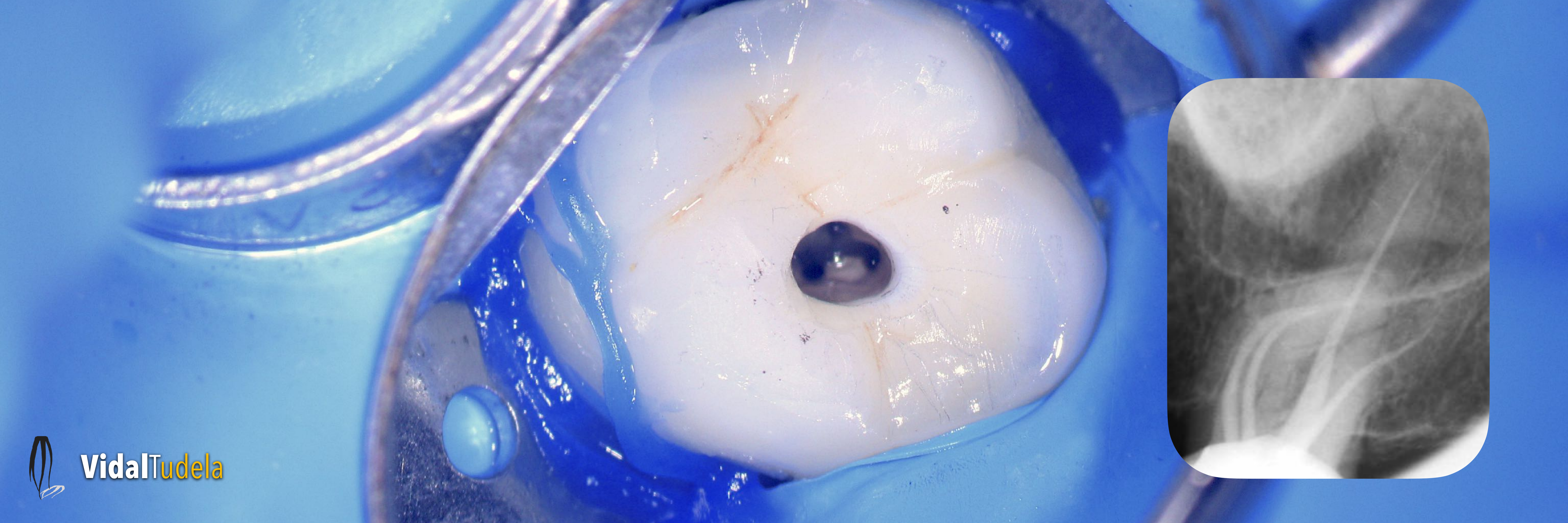


Vital Pulp Therapy



# Conservative Access Cavities

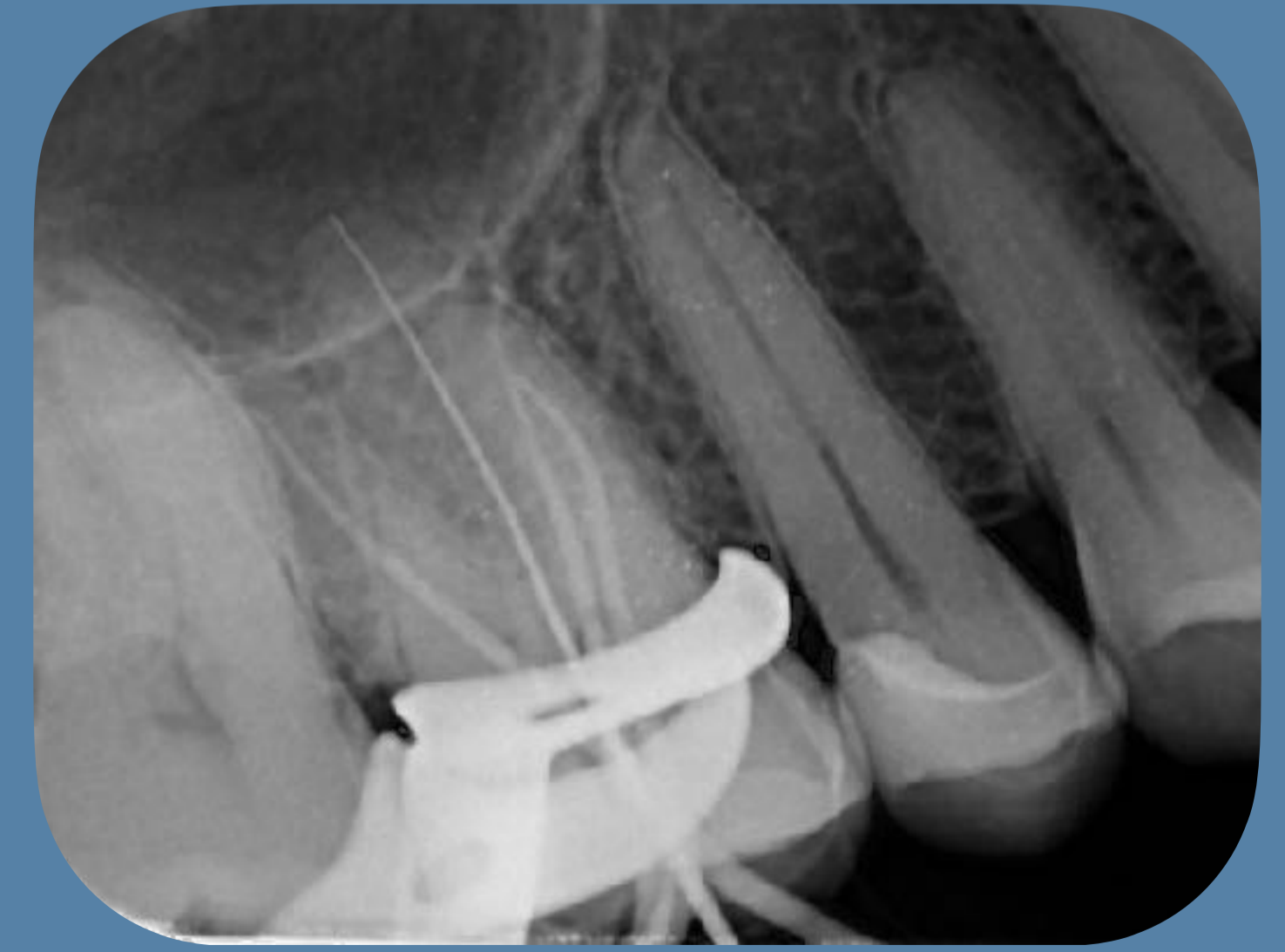
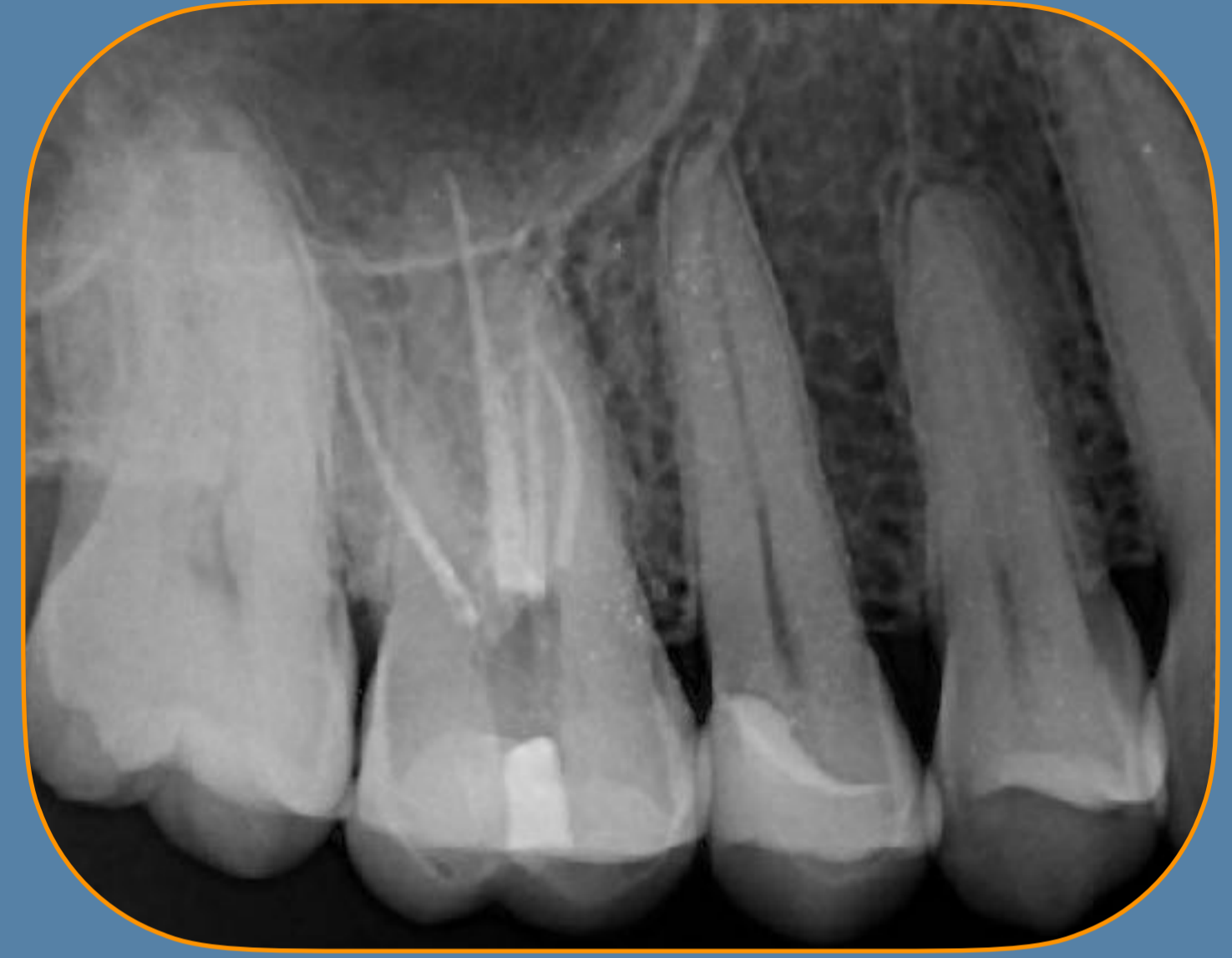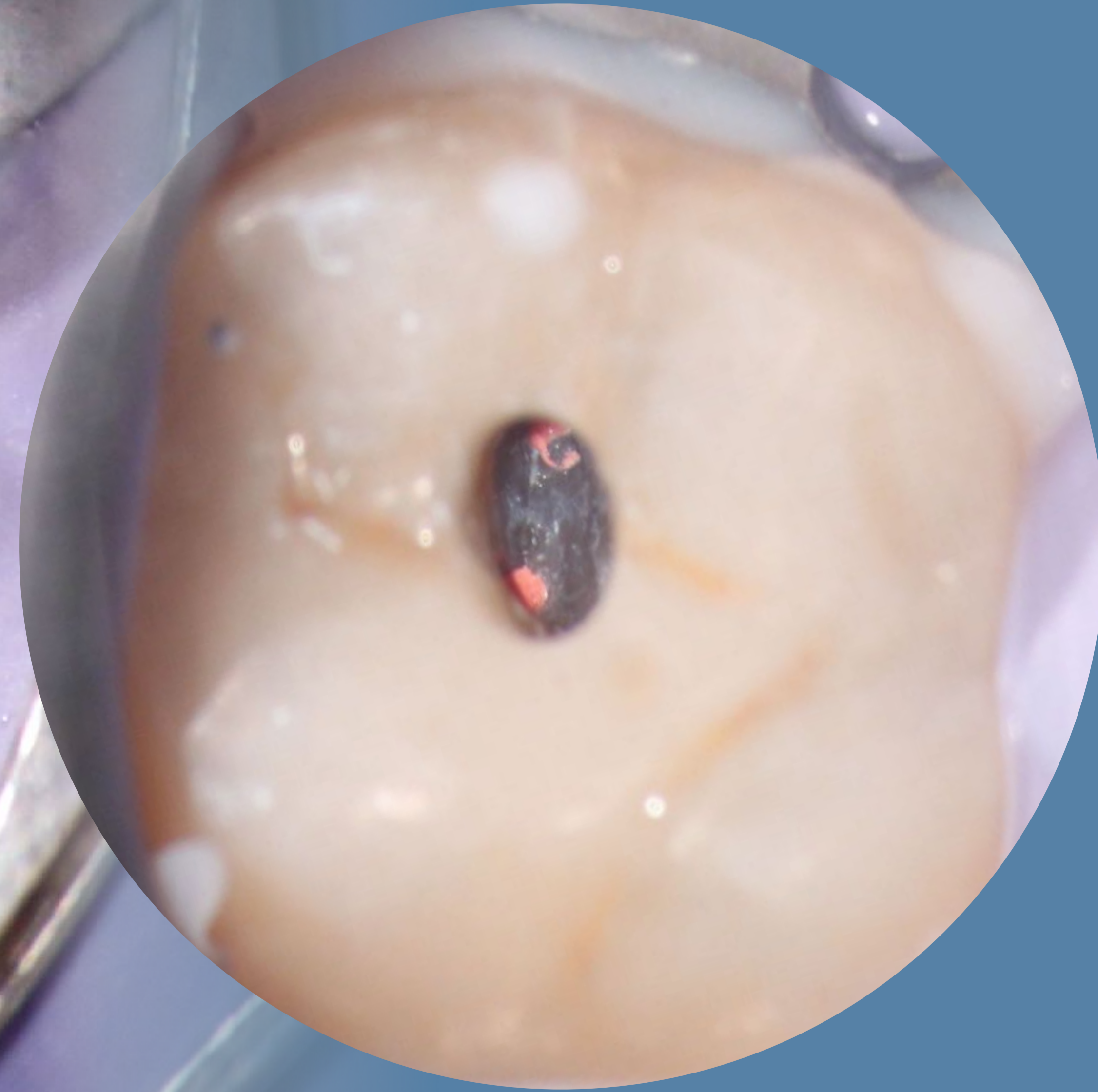

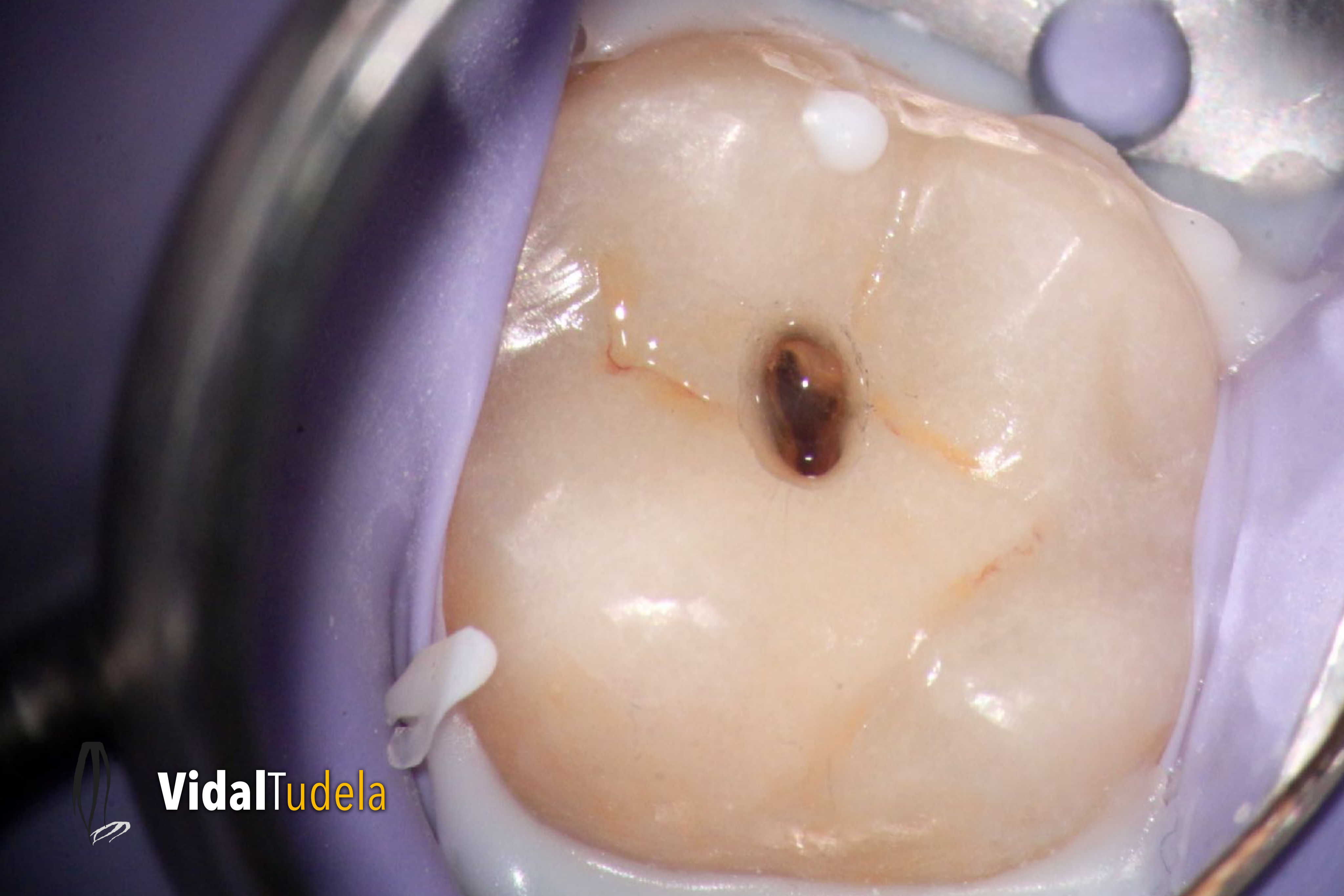


**VidalTudela**

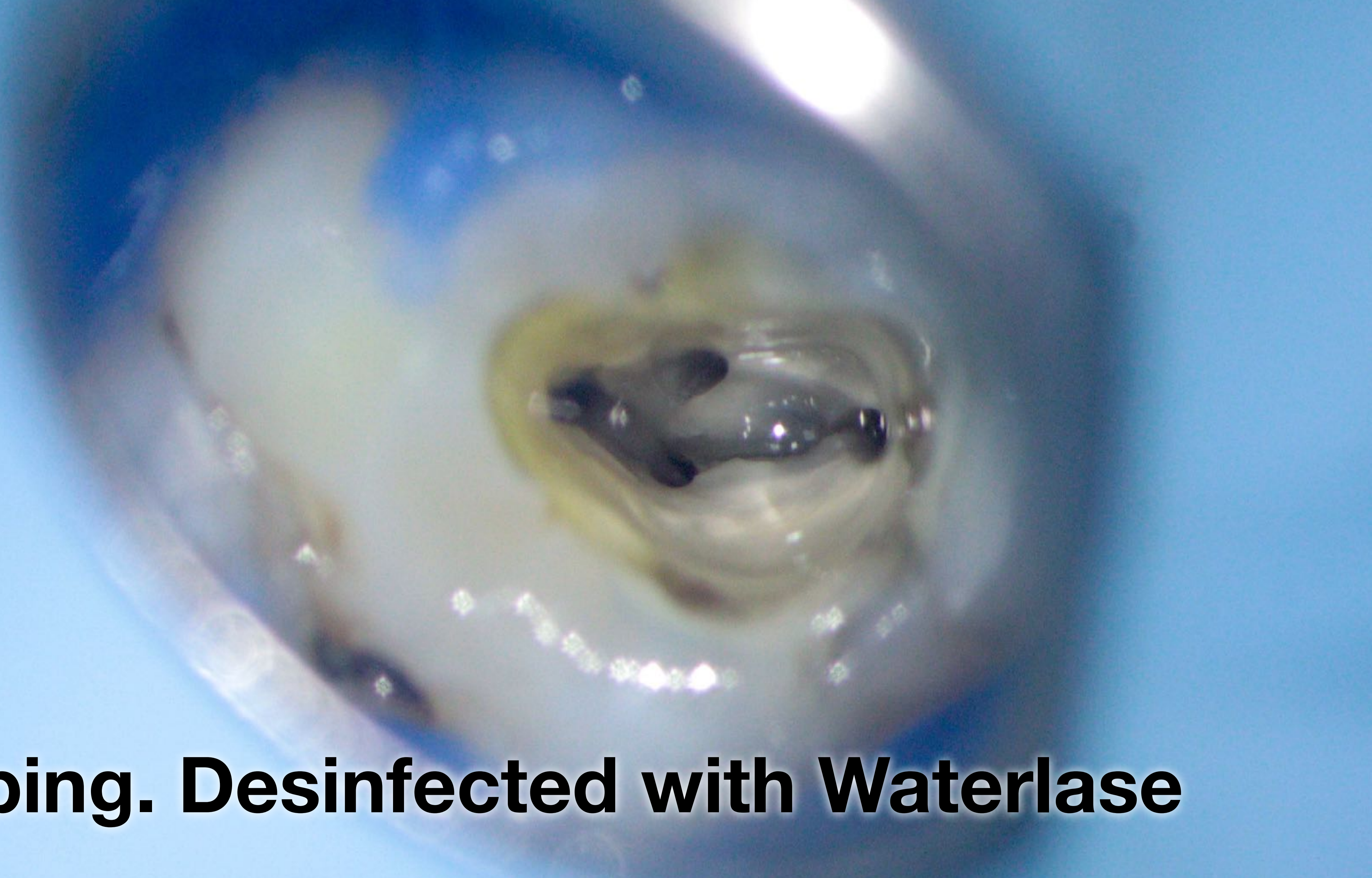
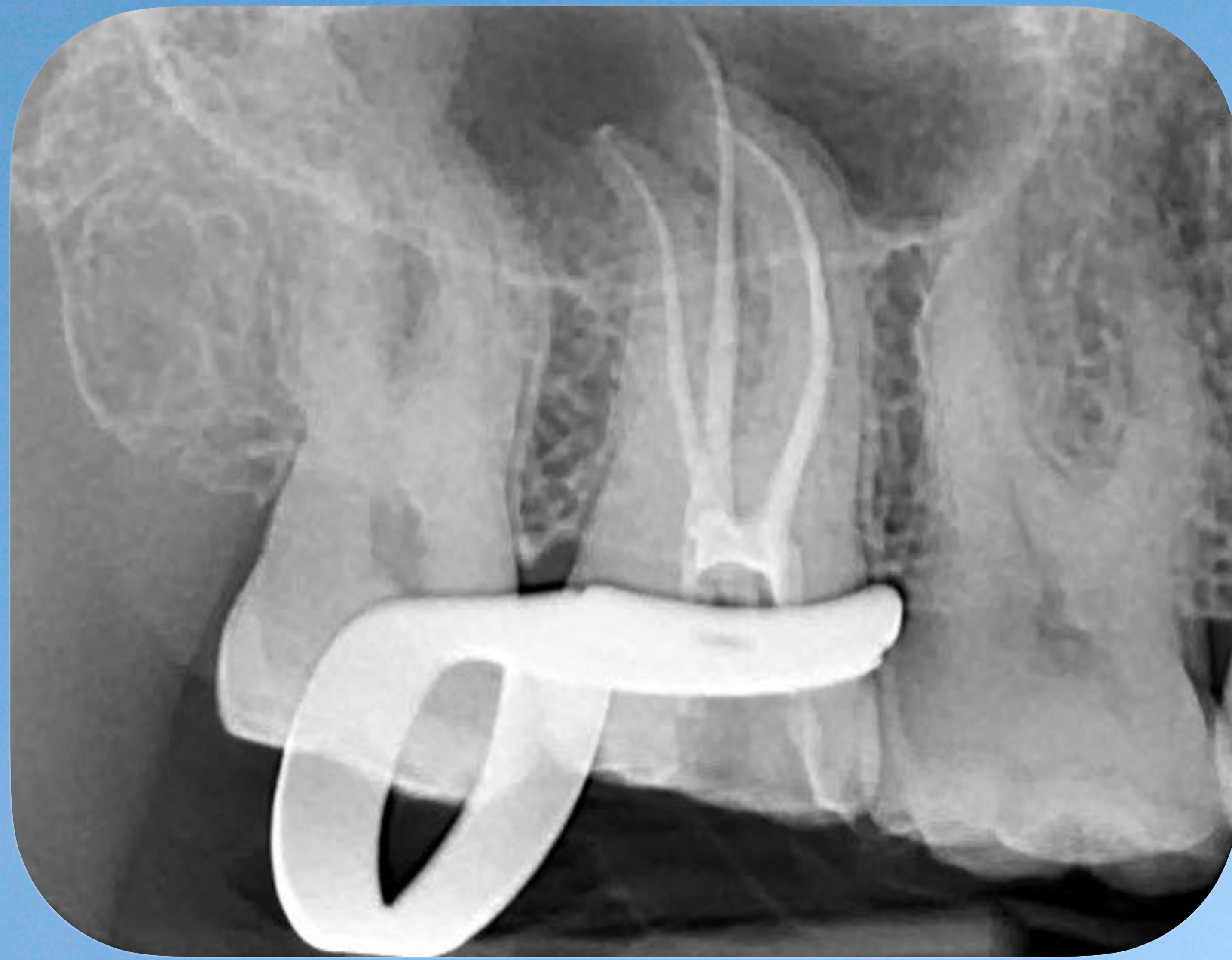


**VidalTudela**



10

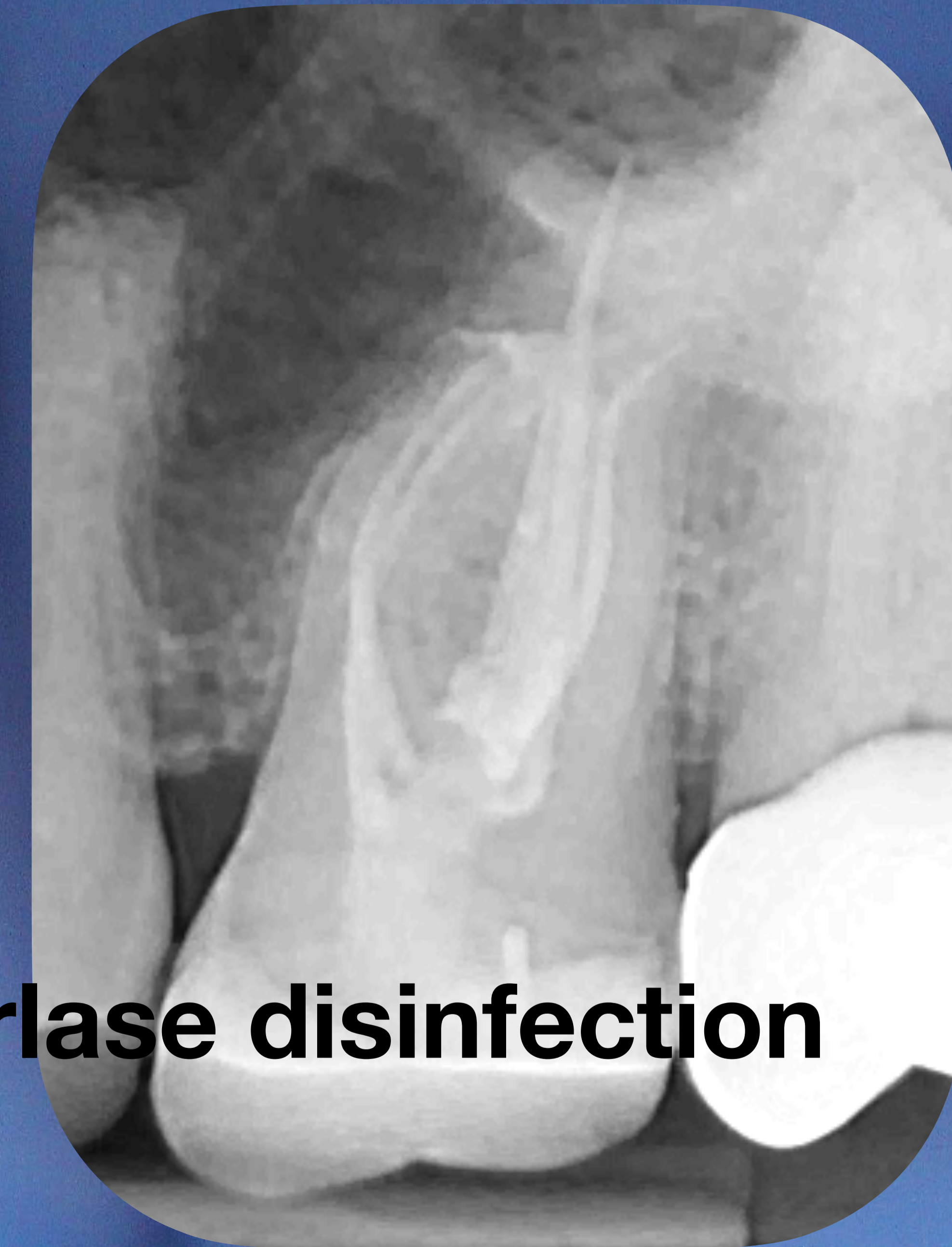Conservative Shaping  
With Waterlase



**Very Conservative Canal shaping. Desinfected with Waterlase**

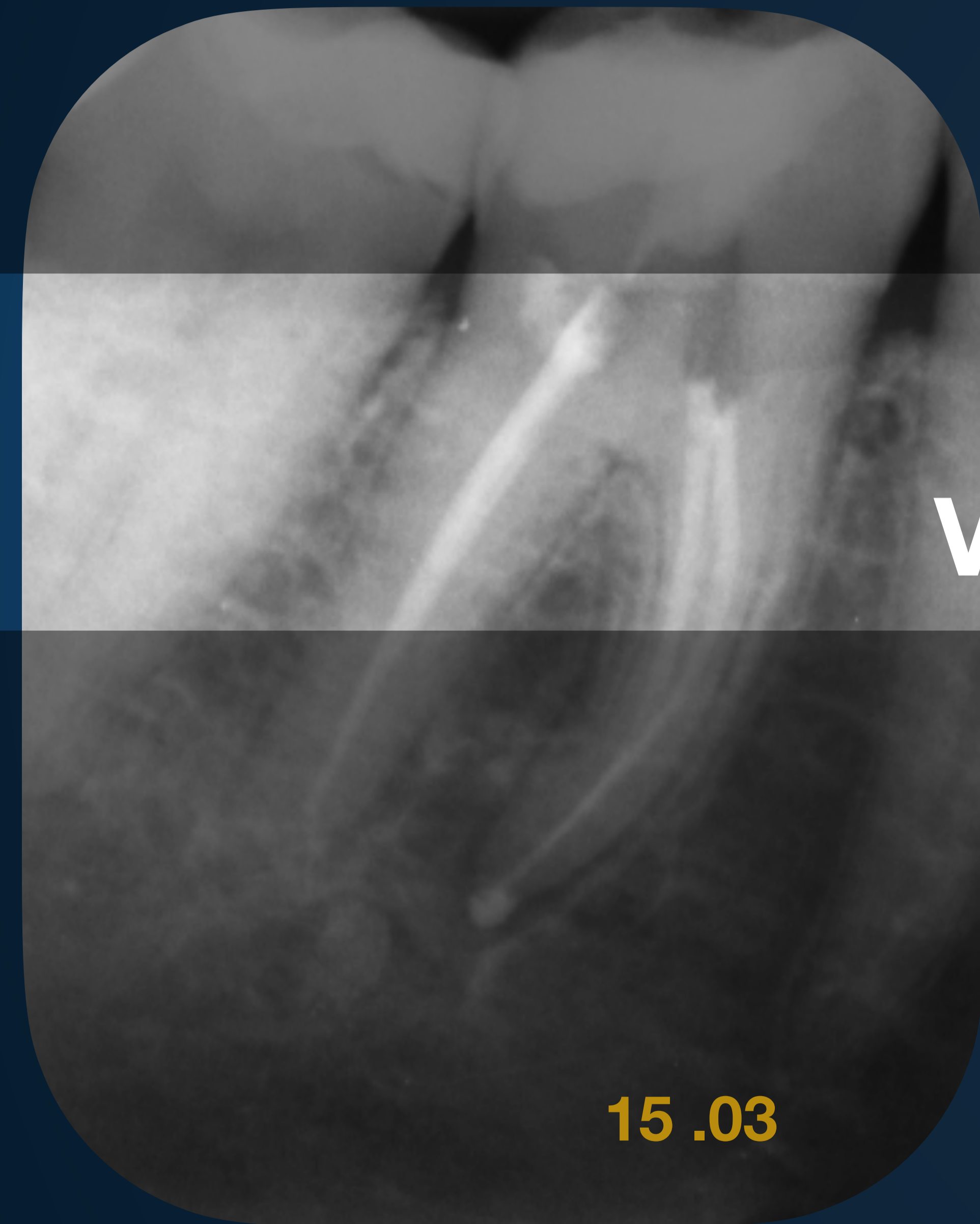


**Preserving Pericervical Dentin . No shaping. Waterlase disinfection**



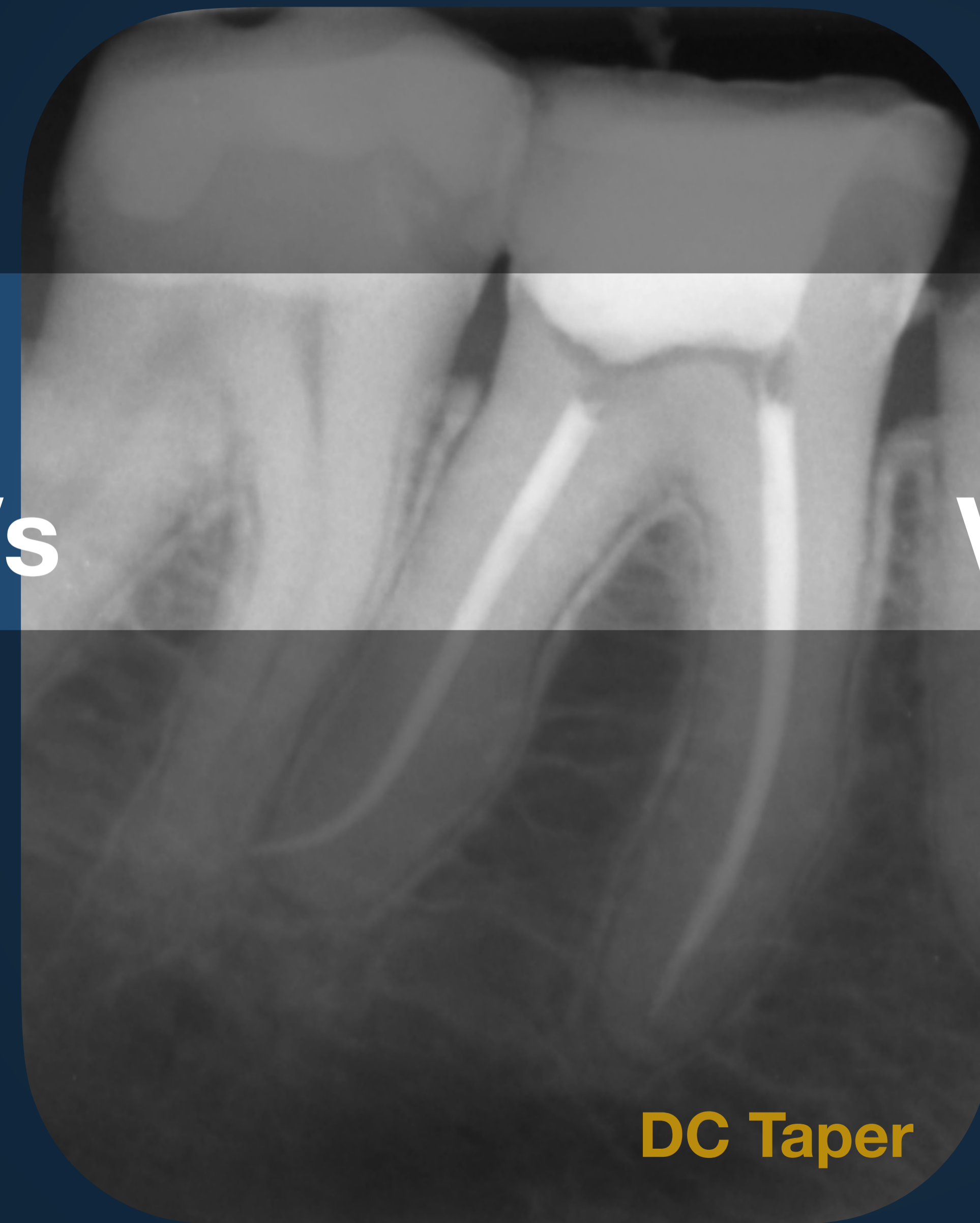Preserving pericervical dentin . No  
shaping. Waterlase disinfection

Cervical  
Third



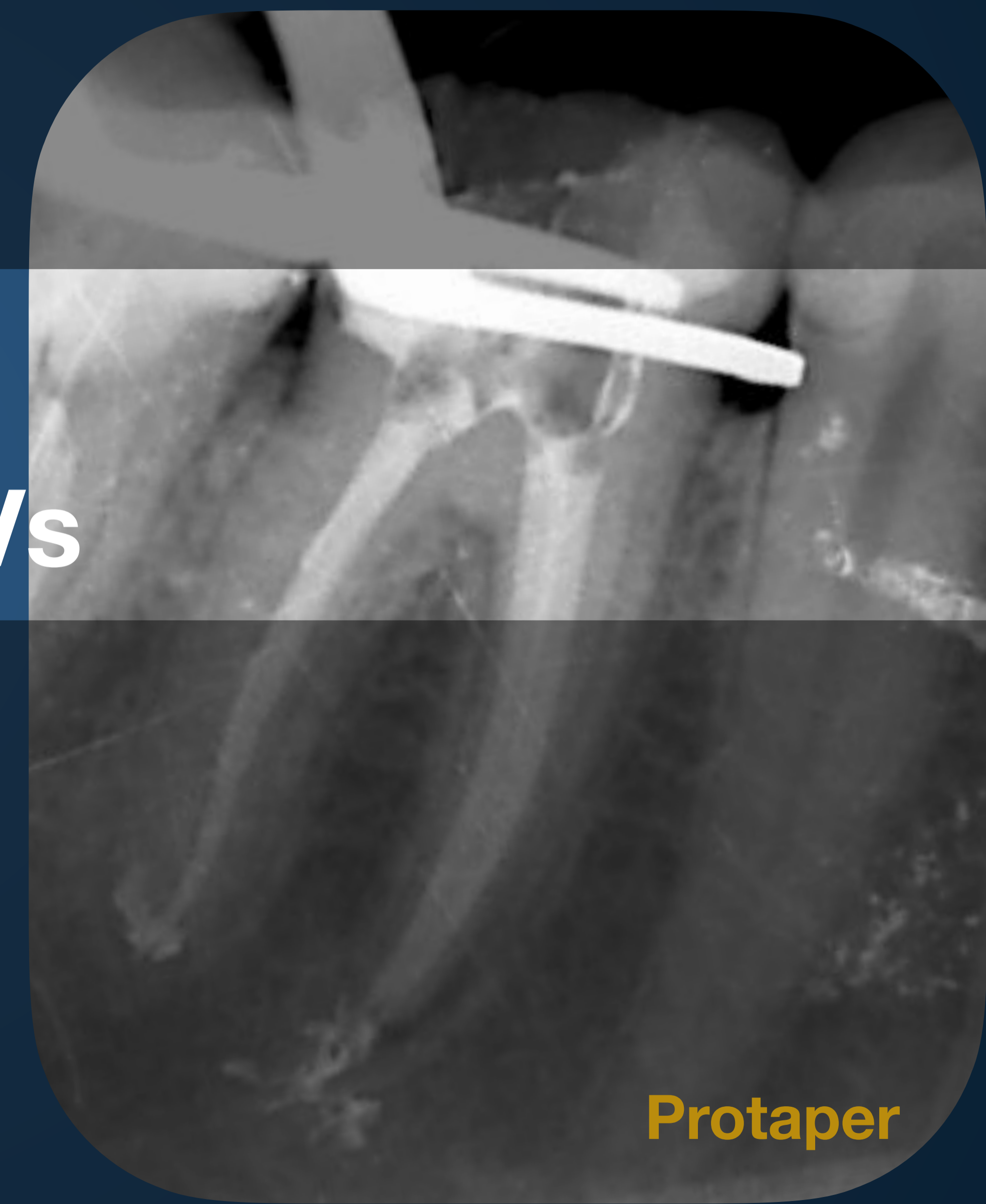15 .03

Vs




DC Taper

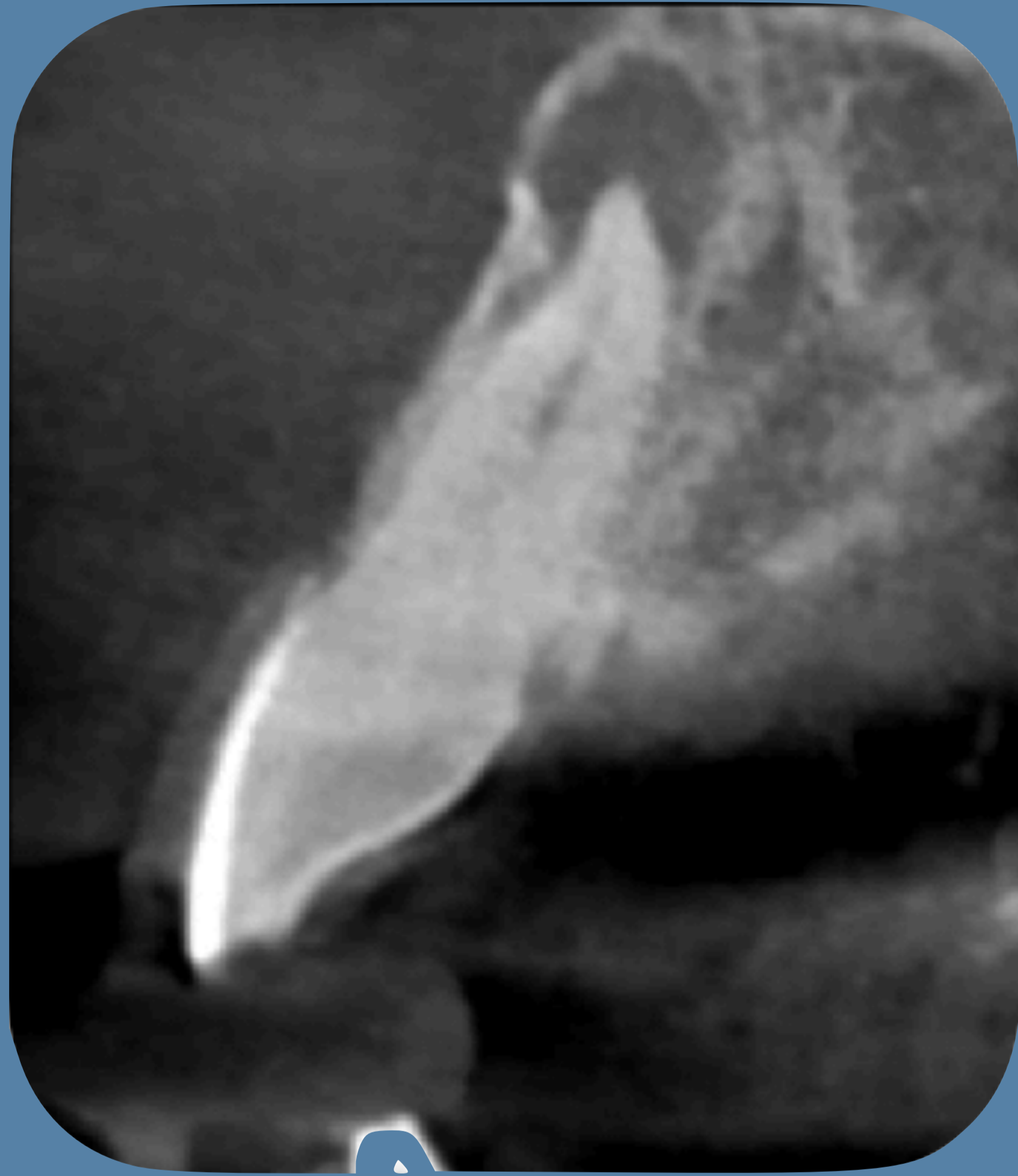
Vs




Protaper



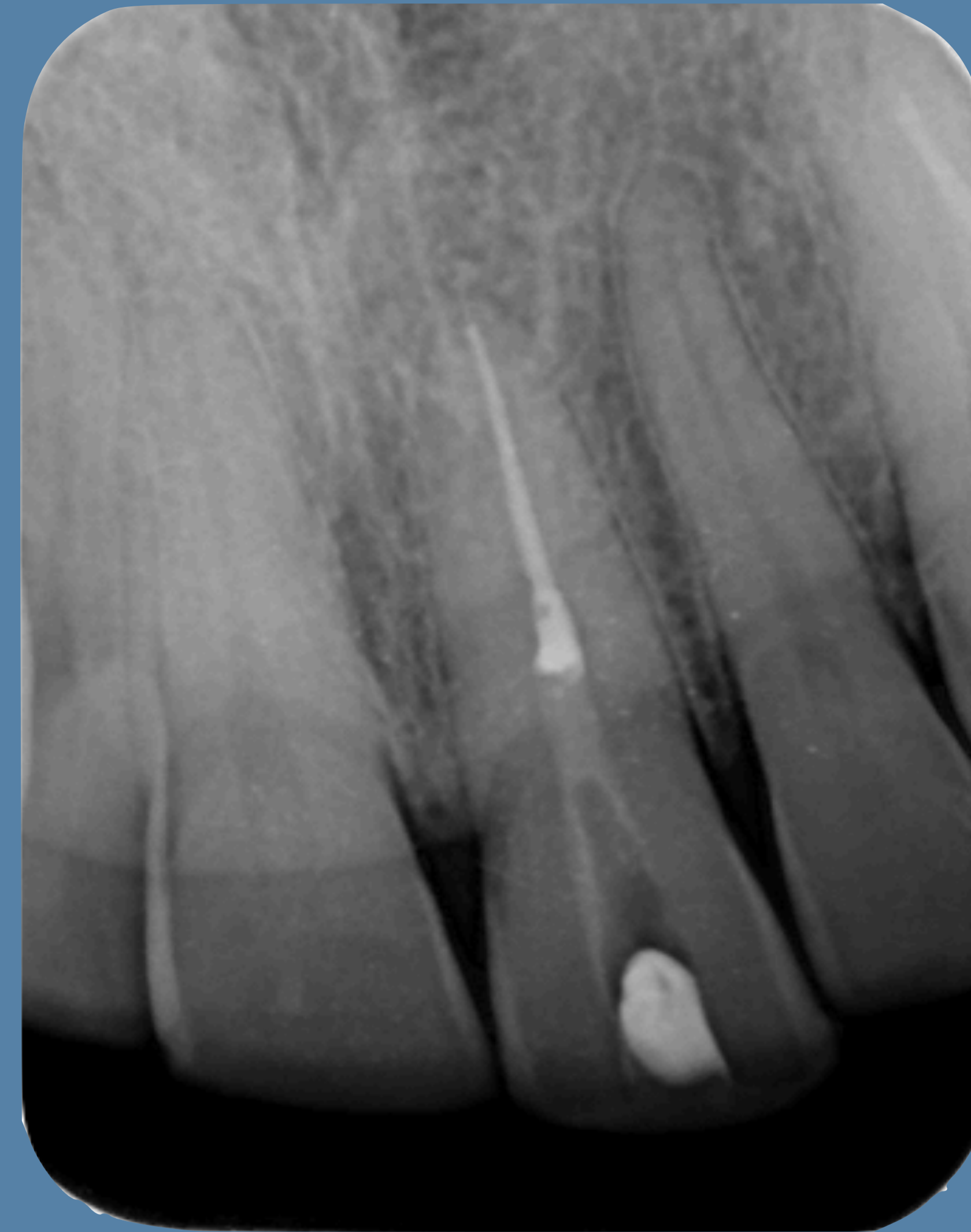
# Management of Calcified Canals with Surgical Guide



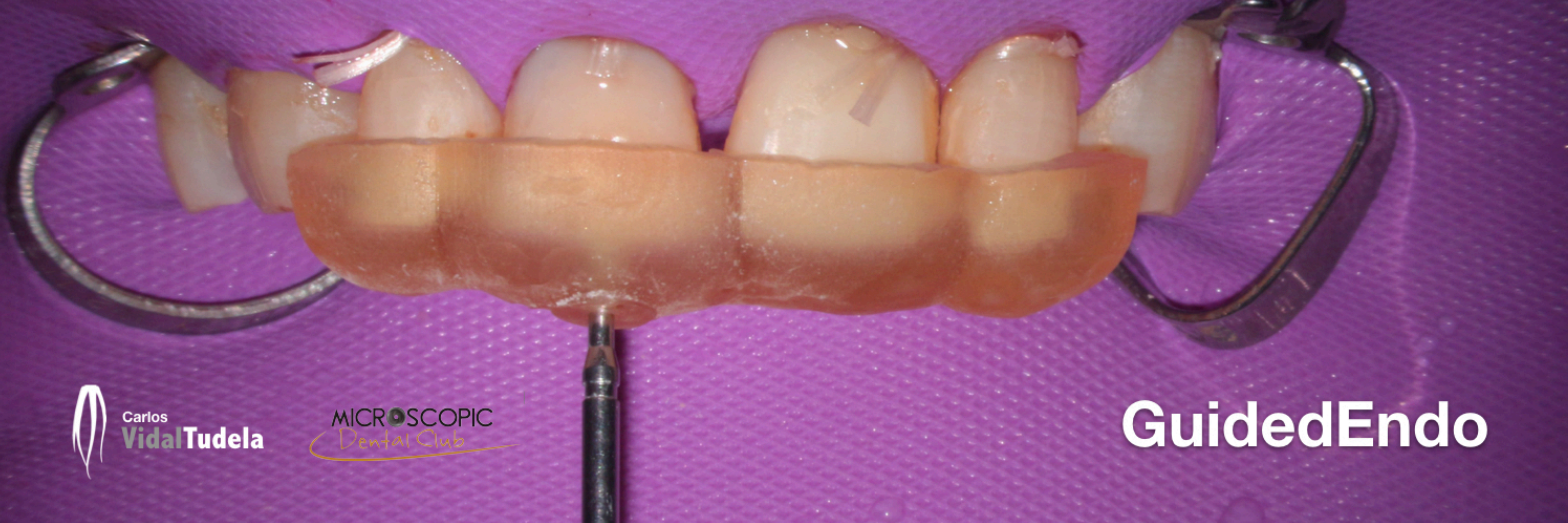**Calcified Canal**



**Surgical Guide**



**Final Rx**



Carlos  
**VidalTudela**

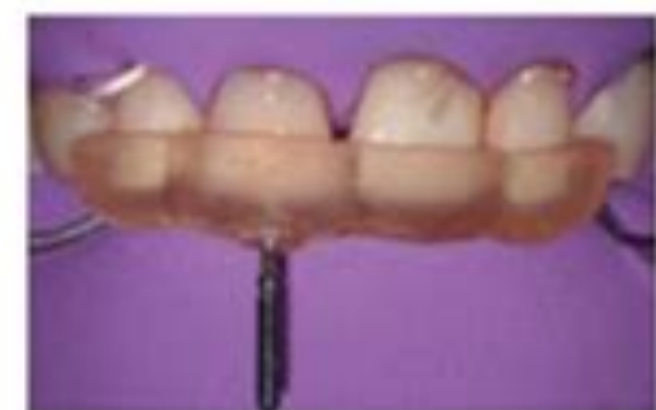MICROSCOPIC  
*Dental Club*

**GuidedEndo**

# JOE

**JOURNAL OF  
ENDODONTICS**

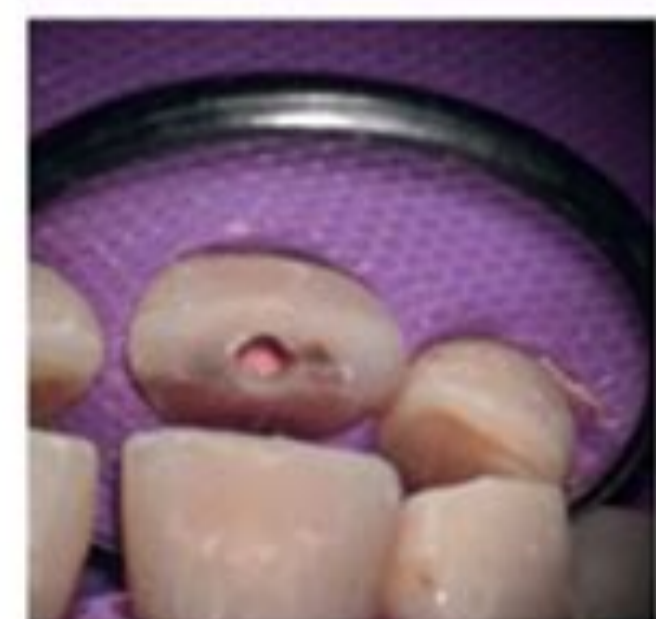February 2021  
Volume 47, Number 2  
www.endodon.com



Guided Endodontic Access in Calcified Teeth  
page 315

**CONSORT RANDOMIZED  
CLINICAL TRIAL**

Effect of Dexamethasone on  
Anesthetic Success Rate of 2%  
Lidocaine during Symptomatic  
Irreversible Pulpitis  
page 161



**CLINICAL RESEARCH**

Dental Anxiety, Fear, and Root  
Canal Treatment Monitoring  
of Heart Rate and Oxygen  
Saturation in Patients Treated  
during the COVID-19 Pandemic  
page 189

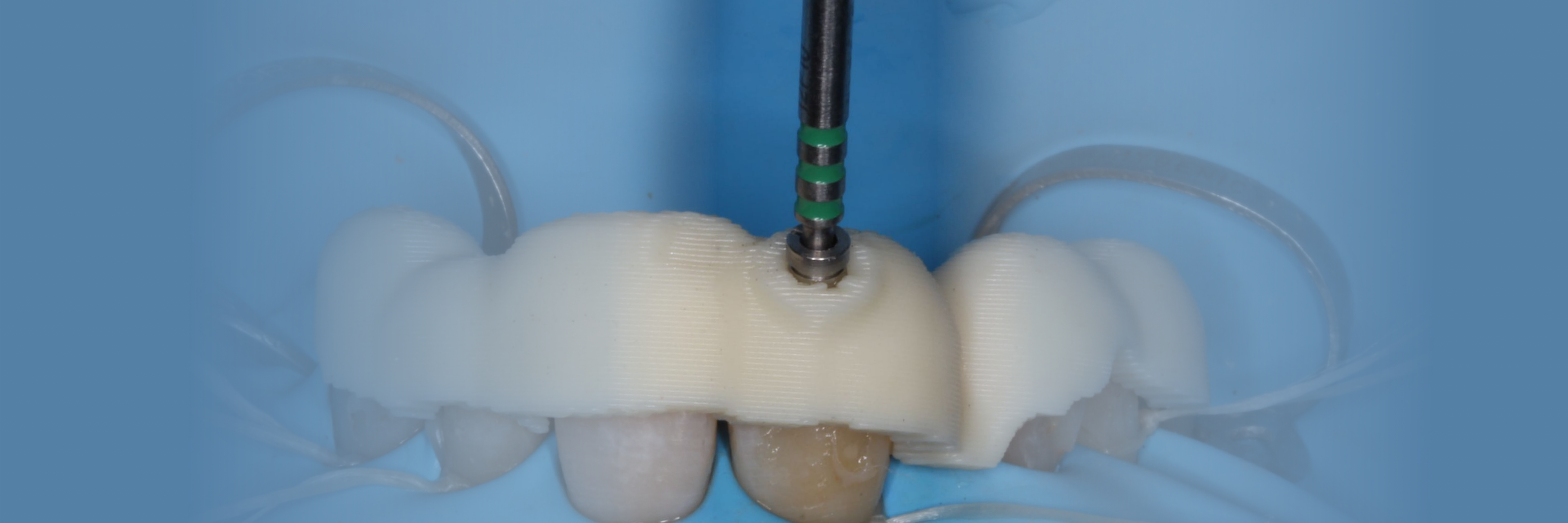
**CLINICAL RESEARCH**

Factors Related to the  
Outcomes of Cracked Teeth  
following Endodontic Treatment  
page 215



american association of  
endodontists

# Journal of Endodontics Cover





2004



2017



2026